

Paper => NEET PG 2022 PYQs

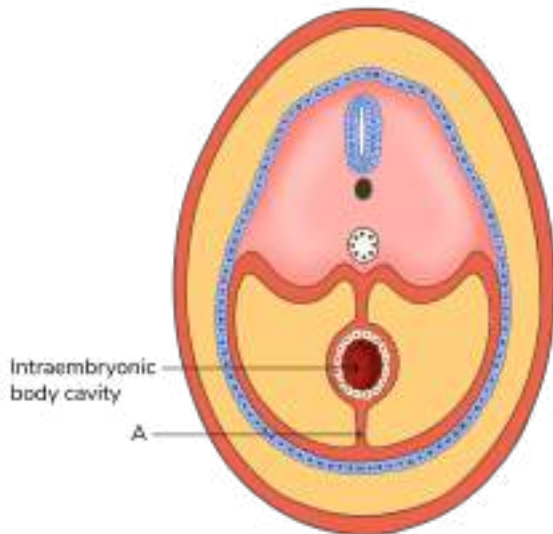
Ques No: 1

Subject: Anatomy

Topic: Abdomen

Sub-Topic:

The structure marked A in the image below gives rise to which of the following structures?



O1:

Gastrosplenic ligament

O2:

Lienorenal ligament

O3:

Falciform ligament

O4:

Gastrophrenic ligament

Ans: 3

Ques No: 2

Subject: Anatomy

Topic: Lower Limb

Sub-Topic:

A patient underwent surgery for the varicose vein. He now complains of sensory loss over the medial aspect of the leg and foot. Which of the following nerves is most likely to be injured?

O1:

Sural nerve

O2:

Superficial peroneal nerve

O3:

Deep peroneal nerve

O4:

Saphenous nerve

Ans: 4

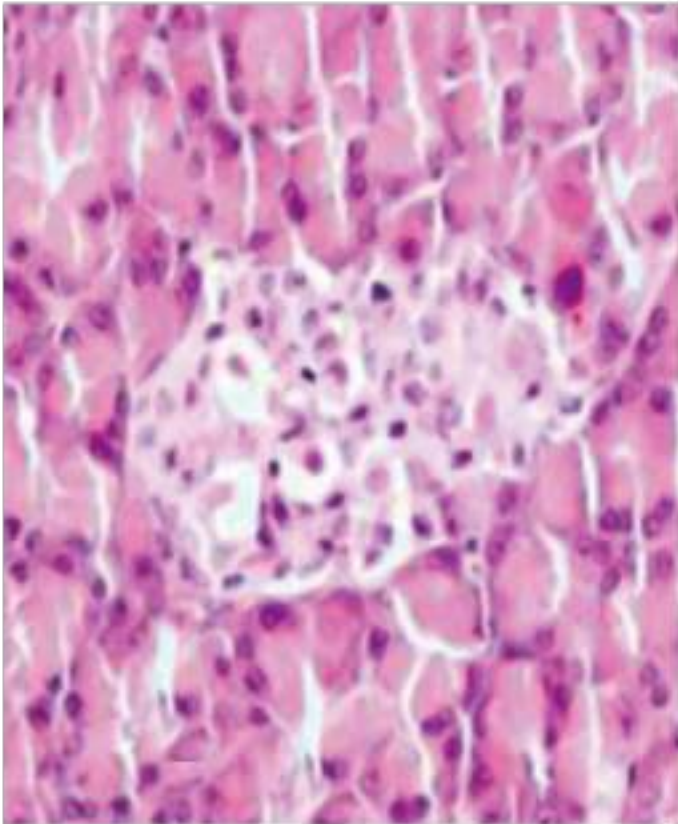
Ques No: 3

Subject: Anatomy

Topic: Histology

Sub-Topic:

Identify the given structure?



O1:

Lymph node

O2:

Glomerulus

O3:

Spleen

O4:

Pancreatic islet cells

Ans: 4

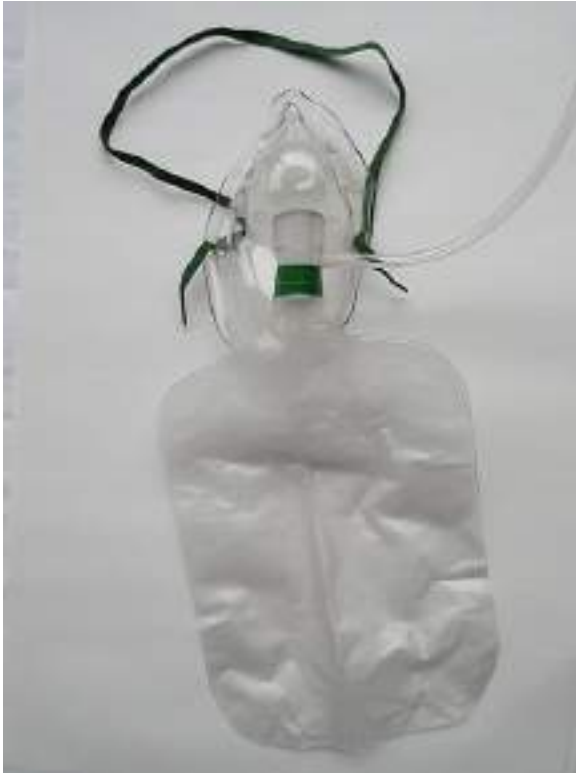Ques No: 4

Subject: Anaesthesia

Topic: Oxygen Therapy and Airway

Sub-Topic:

Identify the mask in the image used for patients with COVID-19 infection.



O1:

Venturi mask

O2:

Hudson mask

O3:

Nebuliser

O4:

Non-rebreathing mask

Ans: 4

Ques No: 5

Subject: Biochemistry

Topic: Carbohydrate Metabolism

Sub-Topic:

A patient from a Mediterranean country visits Africa, where he develops malaria. He is treated

with primaquine and later develops hemolytic anemia. Deficiency of an enzyme involved in which of the following pathways could be the cause?

O1:
Glycolysis

O2:
Gluconeogenesis

O3:
Hexose monophosphate (HMP) pathway

O4:
Luebering-Rapoport pathway

Ans: 3

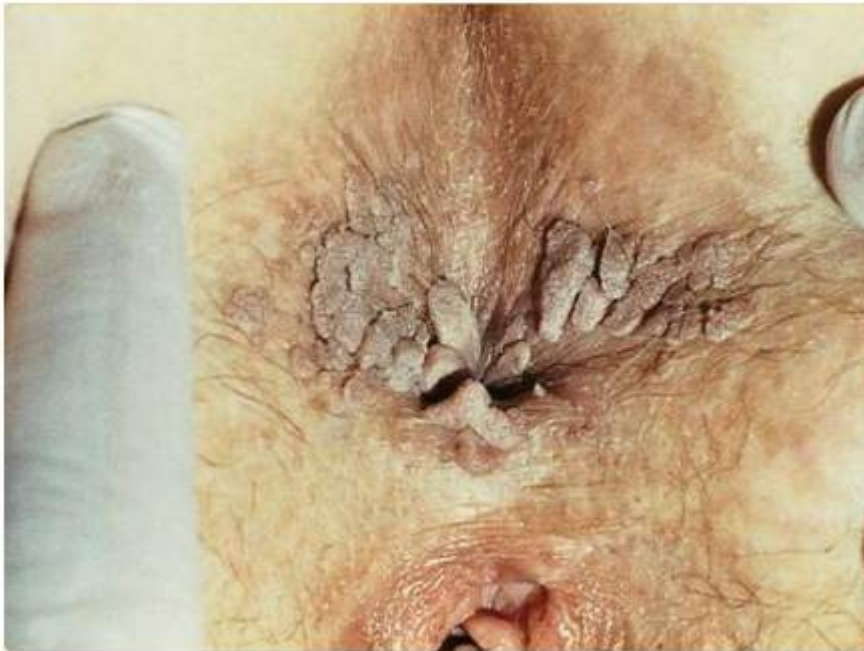Ques No: 6

Subject: Dermatology

Topic: Sexually Transmitted Infections

Sub-Topic:

A patient presents to you with multiple anogenital warts. The biopsy of these lesions showed squamous atypia. Which of the following human papillomavirus types are considered high-risk?



O1:
HPV 2

O2:
HPV 18

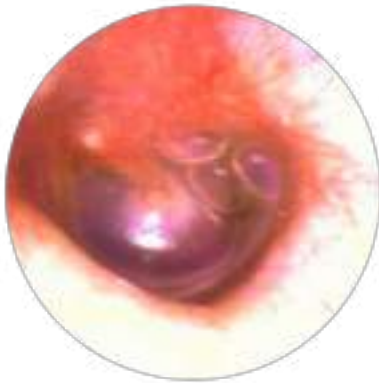O3:
HPV 6

O4:
HPV 11

Ans: 2

Ques No: 7
Subject: ENT
Topic: Ear
Sub-Topic:

A 5-year-old child presents with reduced hearing for the past 2-3 months. The otoscopy finding is given below. What is the most likely diagnosis?



O1:
Myringitis bullosa

O2:
Serous otitis media

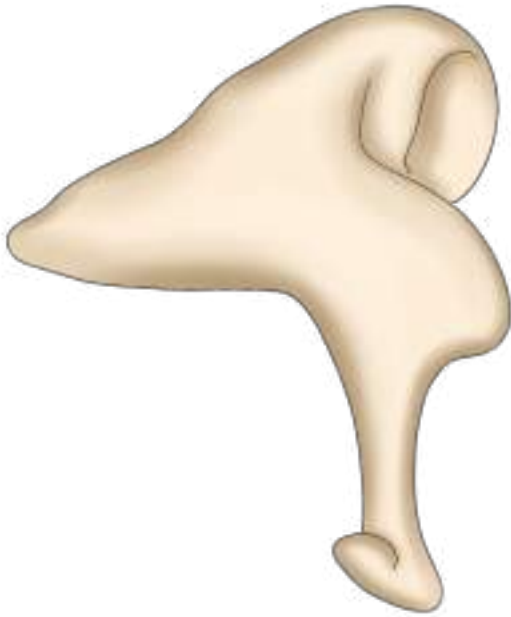O3:
Acute otitis media

O4:
Pneumo Tympanum

Ans: 2

Ques No: 8
Subject: ENT
Topic: Ear
Sub-Topic:

Identify the structure given in the image.



O1:
Malleus

O2:
Incus

O3:
Stapes

O4:
Vomer

Ans: 2

Ques No: 9

Subject: Forensic Medicine

Topic: Toxicology - General

Sub-Topic:

A 56-year-old man presents with fatigue, pallor, and abdominal pain. He reports memory loss and reveals that he works at a battery recycling plant. On examination, a noticeable foot drop in both lower extremities is seen. Laboratory testing shows elevated blood lead levels. Which enzyme is affected in the given scenario?

O1:
Aminolevulinic acid (ALA) dehydratase

O2:
Uroporphyrinogen III

O3:
Uroporphyrinogen I

O4:
Pyruvate dehydrogenase

Ans: 1

Ques No: 10

Subject: Forensic Medicine

Topic: Toxicology - General

Sub-Topic:

A patient came with complaints of hair loss. His wife mentions that she has noticed some behavioral changes. The doctor notices a loss of eyebrows on the lateral side. He then concludes by examining the nails. What is the type of poisoning in this case?

O1:

Thallium

O2:

Arsenic

O3:

Mercury

O4:

Lead

Ans: 1

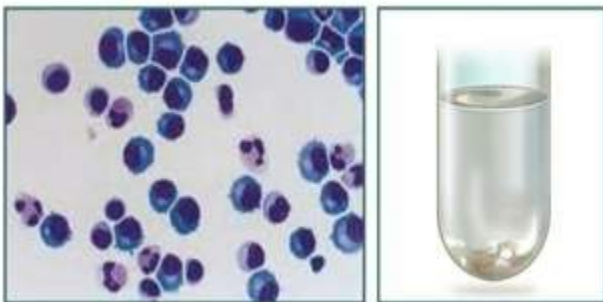
Ques No: 11

Subject: Medicine

Topic: Neurology

Sub-Topic:

The cerebrospinal fluid (CSF) specimen of a patient is shown below along with the microscopy. The report shows mononuclear cytotosis, elevated proteins, and low sugars. Which of the following is the likely etiology?



O1:

Tuberculous meningitis

O2:

Aseptic meningitis

O3:

Bacterial meningitis

O4:

Chemical meningitis

Ans: 1

Ques No: 12

Subject: Medicine

Topic: Neurology

Sub-Topic:

A female patient presents to you with a unilateral headache. It is associated with nausea, photophobia, and phonophobia. What is the drug of choice for acute management?

O1:

Flunarizine

O2:

Sumatriptan

O3:

Propranolol

O4:

Topiramate

Ans: 2

Ques No: 13

Subject: Medicine

Topic: Rheumatology / Connective Tissue Disorder

Sub-Topic:

A patient presents to you with fever, night sweats, ptosis, and bilateral facial nerve palsy. Investigations showed leukocytosis and bilateral hilar lymphadenopathy. Which of the following is the most likely diagnosis?

O1:

Sarcoidosis

O2:

Tuberculosis

O3:

Lymphoma

O4:

Hypersensitive pneumonitis

Ans: 1

Ques No: 14

Subject: Medicine

Topic: Cardiology

Sub-Topic:

A 25-year-old patient is undergoing tooth extraction for dental caries. Which of the following does not require prophylaxis against infective endocarditis?

O1:

Prior history of endocarditis
O2: Atrial septal defect
O3: Unrepaired cyanotic heart disease
O4: Prosthetic heart valves
Ans: 2

<p>Ques No: 15 Subject: Medicine Topic: Liver Sub-Topic:</p> <p>A patient presents to the emergency department with a history of ingestion of ten tablets of paracetamol. He has developed oliguria and liver function tests show deranged values. Which of the following can be used in the management of this condition?</p>
O1: N-acetylcysteine
O2: Dopamine
O3: Ursodeoxycholic acid
O4: Furosemide
Ans: 1

<p>Ques No: 16 Subject: Medicine Topic: Cardiology Sub-Topic:</p> <p>A patient presents to you with an irregularly irregular pulse of 120/minutes and a pulse deficit of 20. Which of the following would be the jugular venous pressure (JVP) finding?</p>
O1: Absent p wave
O2: Absent a wave
O3: Cannon a wave
O4: Raised JVP with normal waveform
Ans: 2

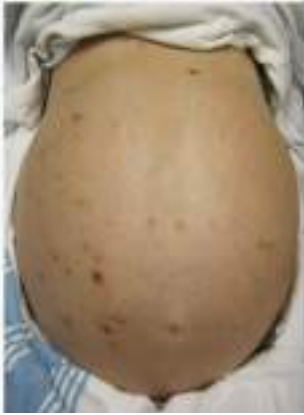Ques No: 17

Subject: Medicine

Topic: GIT

Sub-Topic:

A patient with a history of chronic liver disease presents with abdominal distension, jaundice, and pruritis. Ascitic fluid analysis revealed a neutrophil count >650 per cubic mm. What is the most likely diagnosis?



O1:

Spontaneous bacterial peritonitis

O2:

Malignant ascites

O3:

Tubercular ascites

O4:

Intestinal obstruction

Ans: 1

Ques No: 18

Subject: Medicine

Topic: GIT

Sub-Topic:

Laboratory investigations of a patient being evaluated for jaundice show elevated bilirubin and alkaline phosphatase levels. Levels of the remaining liver enzymes are normal. What is the likely diagnosis?

O1:

Obstructive jaundice

O2:

Hemolytic jaundice

O3:

Hepatic jaundice

O4:

Prehepatic jaundice

Ans: 1

Ques No: 19

Subject: Medicine

Topic: Cardiology

Sub-Topic:

An 11-year-old child with a history of streptococcal pharyngitis presents you with fever and arthralgia. There is no past history of rheumatic heart disease or features of carditis or valvular disease. How often is 6,00,000 IU of benzathine penicillin recommended for prophylaxis of rheumatic heart disease?

O1:

Immediately

O2:

Thrice weekly lifelong

O3:

Once in three weeks for 5 years or till the age of 18, whichever is longer

O4:

Once in three weeks for 10 years or till the age of 25, whichever is longer

Ans: 3

Ques No: 20

Subject: Medicine

Topic: Endocrinology

Sub-Topic:

Which of the following is not seen in MEN 2B syndrome?

O1:

Megacolon

O2:

Parathyroid adenoma

O3:

Mucosal neuroma

O4:

Marfanoid habitus

Ans: 2

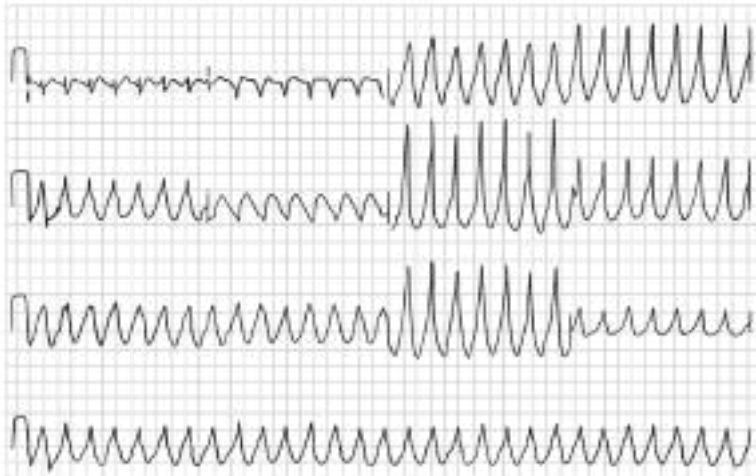
Ques No: 21

Subject: Medicine

Topic: Cardiology

Sub-Topic:

A patient with coronary artery disease presents to you with chest pain and palpitations. The ECG is shown below. Which of the following can be used in the management?



O1:

Oral metoprolol

O2:

Oral amiodarone

O3:

Intravenous amiodarone

O4:

Intravenous metoprolol

Ans: 3

Ques No: 22

Subject: Microbiology

Topic: Parasitology

Sub-Topic:

Microfilariae with sheathed tail and two nuclei at the tail is suggestive of?

O1:

Wuchereria bancrofti

O2:

Brugia malayi

O3:

Loa loa

O4:

Onchocerca volvulus

Ans: 2

Ques No: 23

Subject: Gynaecology & Obstetrics

Topic: Obstetrics

Sub-Topic:

A pregnant lady with 34 weeks of amenorrhea has the following findings: LDH- 700 IU/L, platelets – 75,000/mm³, serum bilirubin- 1.5mg/dL, SGOT-200 U/L, SGPT-150U/L, and BP -140/96 mm Hg. Her coagulation profile and renal function tests are normal. What is the diagnosis?

LDH- Lactate dehydrogenase

SGOT- Serum glutamic-oxaloacetic transaminase / AST- Asparate transaminase

SGPT- Serum glutamic pyruvic transaminase / ALT- Alanine transaminase

O1:

HELLP syndrome

O2:

Acute fatty liver of pregnancy

O3:

Viral hepatitis

O4:

Intrahepatic cholestasis

Ans: 1

Ques No: 24

Subject: Gynaecology & Obstetrics

Topic: Obstetrics

Sub-Topic:

A woman at 26 weeks of gestation presents for routine evaluation. On examination, fundal height corresponds to 24 weeks. Ultrasonography revealed decreased amniotic fluid. Which of the following conditions would have led to this presentation?

O1:

Renal agenesis

O2:

Tracheoesophageal fistula

O3:

Cardiac abnormalities

O4:

Ureteral stricture

Ans: 1

Ques No: 25

Subject: Gynaecology & Obstetrics


Topic: Obstetrics

Sub-Topic:

A type 1 diabetic mother is on magnesium sulfate infusion post – cesarean section for preeclampsia. She develops delirium and is drowsy. She has a respiratory rate of 10/min, random blood glucose level of 240 mg / dL, oliguria, and bilaterally absent knee reflex. What is the cause of her condition?

O1:

Magnesium sulfate toxicity
O2: Diabetic ketoacidosis
O3: Eclampsia
O4: Diabetes insipidus
Ans: 1

<p>Ques No: 26</p> <p>Subject: Gynaecology & Obstetrics</p> <p>Topic: Gynecology</p> <p>Sub-Topic:</p> <p>Identify the type of hymen shown in the image.</p> 
O1: Imperforate hymen
O2: Semilunar hymen
O3: Septate hymen
O4: Annular hymen
Ans: 3

<p>Ques No: 27</p> <p>Subject: Gynaecology & Obstetrics</p> <p>Topic: Gynecology</p> <p>Sub-Topic:</p> <p>While discharging a patient who underwent a vesicovaginal fistula repair, which of the following would you recommend?</p>
O1:

Sexual abstinence for 3 months and avoid pregnancy for a year

O2:

Sexual abstinence for 3 weeks and avoid pregnancy for 6 months

O3:

Sexual abstinence for 6 weeks and avoid pregnancy for a year

O4:

Sexual abstinence for 6 months and avoid pregnancy for 6 years

Ans: 1

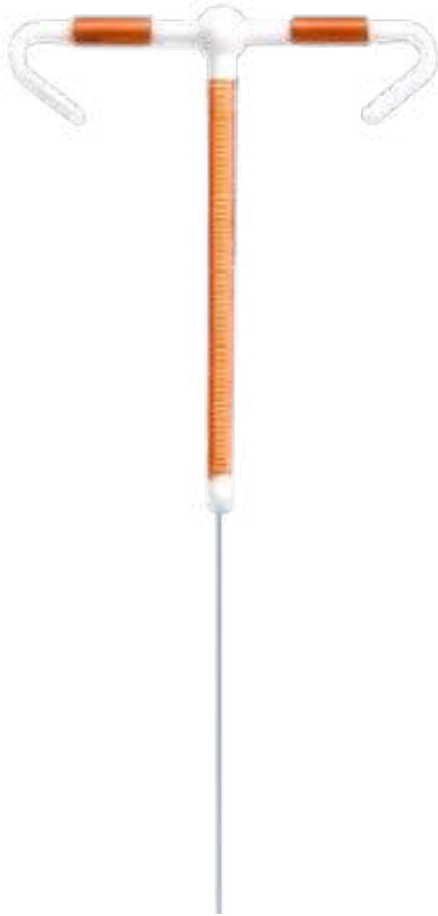Ques No: 28

Subject: Gynaecology & Obstetrics

Topic: Gynecology

Sub-Topic:

Which of the following is an absolute contraindication for the insertion of the device shown in the image below?



O1:

Menstruation

O2:

Trophoblastic disease

O3:

Immediately after delivery

O4:

Ruptured condom during intercourse

Ans: 2

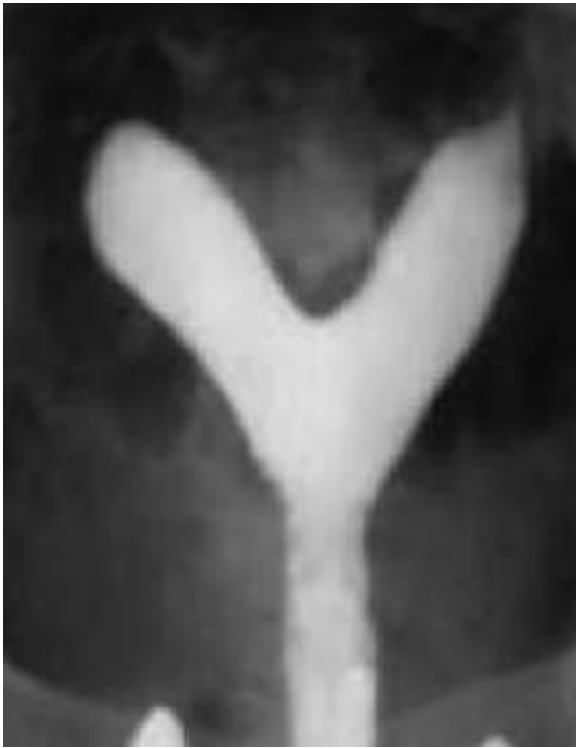Ques No: 29

Subject: Gynaecology & Obstetrics

Topic: Gynecology

Sub-Topic:

A 20 year old woman is evaluated for primary infertility. Hysterosalpingography was done and reveals the finding shown below. What is the anomaly seen in the image?



O1:

Septate uterus

O2:

Uterine didelphys

O3:

Bicornuate uterus

O4:

Unicornuate uterus

Ans: 1

Ques No: 30

Subject: Gynaecology & Obstetrics

Topic: Obstetrics

Sub-Topic:

A pregnant woman with no other comorbid conditions develops preeclampsia. She enquires about the cause of her condition. The doctor explains that it is due to the failure of the invasion of:

O1:

Spiral artery by villous trophoblasts

O2:

Radial artery by cytotrophoblasts

O3:

Spiral artery by extravillous trophoblasts

O4:

Arcuate artery by extravillous trophoblasts

Ans: 3

Ques No: 31

Subject: Gynaecology & Obstetrics

Topic: Obstetrics

Sub-Topic:

A woman with an obstetric score of G2P1 comes to the clinic at 14 weeks of gestation for her antenatal checkup. A uterine artery doppler was suggested by the doctor. What would it detect?

O1:

Early onset preeclampsia

O2:

Late – onset preeclampsia

O3:

Fetal growth restriction

O4:

Placenta accreta

Ans: 1

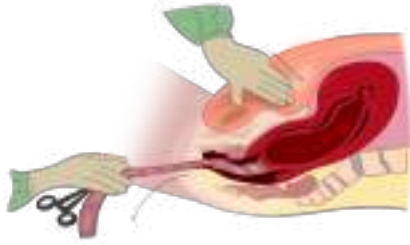Ques No: 32

Subject: Gynaecology & Obstetrics

Topic: Obstetrics

Sub-Topic:

While conducting a delivery, you perform the maneuver shown below. Following this, there is incomplete separation of the placenta and massive hemorrhage. What is your next step in management?



O1:
Start oxytocin infusion and wait for spontaneous delivery of placenta

O2:
Uterine massage

O3:
Arrange for blood and use Crede's method for placental delivery

O4:
Manual removal of placenta

Ans: 4

Ques No: 33

Subject: Gynaecology & Obstetrics

Topic: Obstetrics

Sub-Topic:

A female patient collapses soon after delivery. There is profuse bleeding and features of disseminated intravascular coagulation. Which of the following is the most likely etiology?

O1:
Amniotic fluid embolism

O2:
Uterine prolapse

O3:
Peripartum cardiomyopathy

O4:
Rupture of the uterus

Ans: 1

Ques No: 34

Subject: Gynaecology & Obstetrics

Topic: Obstetrics

Sub-Topic:

You are examining a multigravida in the second stage of labor for the past two hours. On examination, contractions are adequate, the cervix is dilated with the head at station 0 with molding 2+ and caput 2+. The sagittal suture is in the right occipitotransverse position. The fetal heart rate is 140 beats / minute. Which of the following is carried out for the management of this patient?

O1:

Midpelvic forceps

O2:

Vacuum -assisted delivery

O3:

Wait for an hour for spontaneous labor

O4:

Lower segment cesarean section

Ans: 4

Ques No: 35

Subject: Gynaecology & Obstetrics

Topic: Obstetrics

Sub-Topic:

A primigravida presents to the labor room at 40 weeks of gestation with lower abdominal pain. She has been in labor for 3 hours. Which of the following will determine if she is in active labor?

O1:

Fetal head 5/5 palpable on abdominal examination

O2:

Two contractions lasting for 10 seconds in 10 minutes

O3:

More than 5 cm cervical dilatation with complete effacement

O4:

Rupture of membranes

Ans: 3

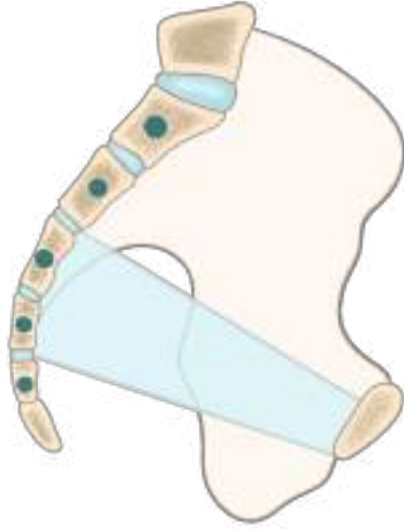Ques No: 36

Subject: Gynaecology & Obstetrics

Topic: Obstetrics

Sub-Topic:

Identify the blue – colored area shown in the image below



O1:
Obstetric outlet

O2:
Anatomical outlet

O3:
Pelvic inlet

O4:
Midpelvis

Ans: 4

Ques No: 37

Subject: Gynaecology & Obstetrics

Topic: Obstetrics

Sub-Topic:

What will be the level of the uterus on the second – day post delivery?

O1:
One finger breadth below umbilicus

O2:
Two finger breadths below umbilicus

O3:
Three finger breadths below umbilicus

O4:
Four finger breadths below umbilicus

Ans: 1

Ques No: 38

Subject: Gynaecology & Obstetrics

Topic: Obstetrics

Sub-Topic:

A primigravida woman at 12 weeks of gestation comes to the antenatal clinic for nutritional advice. Which of the following will you recommend?

O1:

Additional 300 kcal in 2nd trimester

O2:

Additional 300 kcal in 1st trimester

O3:

Additional 400 kcal in 3rd trimester

O4:

Additional 300 kcal throughout the pregnancy

Ans: 1

Ques No: 39

Subject: Gynaecology & Obstetrics

Topic: Obstetrics

Sub-Topic:

A 40 year old G2P1 woman with 18 weeks of amenorrhea comes with a dilated cervix. The cervical length is 15 mm. In spite of explaining the risks, she insisted on cerclage. Which of the following is a contraindication for cervical cerclage?

O1:

Ruptured membranes

O2:

Prolapse of membranes into the vagina

O3:

Fetal fibronectin positive

O4:

Advanced maternal age

Ans: 2

Ques No: 40

Subject: Gynaecology & Obstetrics

Topic: Obstetrics

Sub-Topic:

A primigravida presents to the emergency room in the early stage of labor with adequate uterine contractions. On per vaginal examination, a gynecoid pelvis is felt, the membranes are ruptured, and the vertex is felt in the right occipito- posterior position. How will you manage this patient?

O1:

Vacuum – assisted delivery

O2: Cesarean section
O3: Normal vaginal delivery
O4: Forceps delivery
Ans: 3

<p>Ques No: 41 Subject: Gynaecology & Obstetrics Topic: Obstetrics Sub-Topic:</p> <p>A pregnant patient, with a history of classical cesarean section in view of fetal growth retardation in the previous pregnancy, presents to you. She is currently at 35 weeks of gestation with breech presentation. What is the next step in management?</p>
O1: Cesarean section at 37 weeks
O2: Advice USG and visit after 2 weeks
O3: Internal podalic version followed by vaginal delivery
O4: External cephalic version at 36 weeks
Ans: 1

<p>Ques No: 42 Subject: Gynaecology & Obstetrics Topic: Obstetrics Sub-Topic:</p> <p>A primigravida at 22 weeks of gestation presents to you with profuse vaginal bleeding. Her blood pressure and glucose levels are within normal limits. Placental implantation at which of the following sites can cause this?</p>
O1: Internal OS
O2: Fallopian tube
O3: Ovarian
O4: Abdominal
Ans: 1

Ques No: 43

Subject: Gynaecology & Obstetrics

Topic: Gynecology

Sub-Topic:

A female patient presents to you with six weeks of amenorrhea, associated with abdominal pain and vaginal bleeding with normal blood pressure. Investigations revealed beta – hCG to be 1400 mIU/mL. An ultrasound scan was done which showed a trilaminar endometrium with normal adnexa. What is the next best step in the management of this patient ?

O1:

Repeat beta – hCG after 48 hours

O2:

Repeat ultrasound after 3 days

O3:

Measurement of progesterone

O4:

Laparoscopy

Ans: 1

Ques No: 44

Subject: Gynaecology & Obstetrics

Topic: Gynecology

Sub-Topic:

A 24 year old lactating female with an 18 month old child comes with a history of irregular, heavy bleeding seeking contraceptive advice. Which is the contraceptive of choice?

O1:

Progestasert

O2:

Copper – T 380A

O3:

Mala

O4:

Norethisterone enanthate – depot injection

Ans: 3

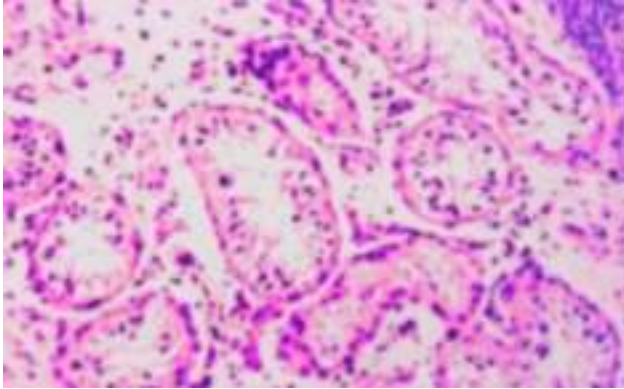
Ques No: 45

Subject: Gynaecology & Obstetrics

Topic: Gynecology

Sub-Topic:

A 25 year old male patient is evaluated for primary infertility. Semen analysis shows azoospermia. A testicular biopsy is done and the image is shown below. The shown finding is consistent with



O1:
Sertoli cell only syndrome

O2:
Testicular atrophy

O3:
Benign testicular neoplasm

O4:
Orchitis

Ans: 1

Ques No: 46

Subject: Gynaecology & Obstetrics

Topic: Obstetrics

Sub-Topic:

A 20 year old woman presented at 7 weeks of gestation, unwilling to continue the pregnancy. What are the drugs used for medical termination of pregnancy in this patient?

O1:
Misoprostol and Medroxyprogesterone

O2:
Misoprostol and Mifepristone

O3:
Mifepristone and Methotrexate

O4:
Mifepristone and Medroxyprogesterone

Ans: 2

Ques No: 47

Subject: Gynaecology & Obstetrics

Topic: Obstetrics

Sub-Topic:

Testosterone helps in the development of various organs in the fetus. Which of the following stimulates its production?

O1:
LH from maternal pituitary

O2:
hCG from placenta

O3:
Inhibin from corpus luteum

O4:
GnRH from fetal hypothalamus

Ans: 2

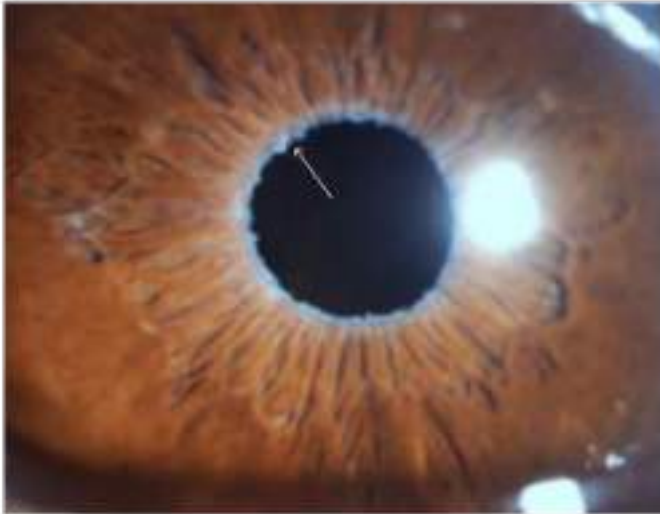Ques No: 48

Subject: Ophthalmology

Topic: Glaucoma

Sub-Topic:

What is the diagnosis?



O1:
Intraocular foreign body

O2:
Pseudoexfoliation syndrome

O3:
Ocular trauma

O4:
Vossius ring

Ans: 2

Ques No: 49

Subject: Ophthalmology

Topic: Uveitis

Sub-Topic:

A patient presents with a history of penetrating injury to the eye. A diagnosis of sympathetic ophthalmitis was confirmed. Which of the following will be seen?

O1:

Acute anterior uveitis

O2:

Pars planitis

O3:

Panuveitis

O4:

Chronic anterior uveitis

Ans: 3

Ques No: 50

Subject: Ophthalmology

Topic: Glaucoma

Sub-Topic:

A diabetic patient presents to you with visual acuity of 6/9 in one eye. Further investigations revealed preretinal hemorrhages with neovascularization at the optic disc. What is the next step in management?

O1:

Focal laser photocoagulation

O2:

Pan-retinal photocoagulation

O3:

Grid laser photocoagulation

O4:

Scleral buckling

Ans: 2

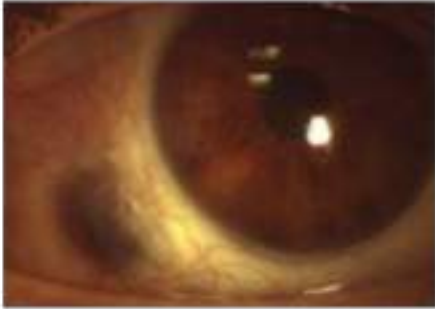
Ques No: 51

Subject: Ophthalmology

Topic: Sclera

Sub-Topic:

A 35-year-old woman is diagnosed with rheumatoid arthritis. What associated complications are shown in the image?



O1:
Scleromalacia perforans

O2:
Ciliary staphyloma

O3:
Coloboma

O4:
Malignant melanoma

Ans: 1

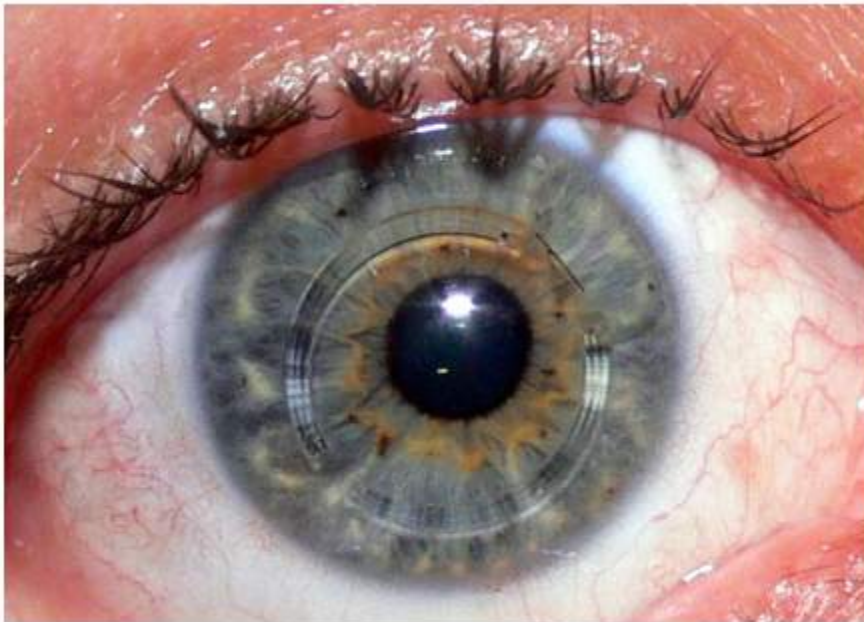
Ques No: 52

Subject: Ophthalmology

Topic: Cornea

Sub-Topic:

What is the indication of this procedure?



O1:
Keratoconus

O2:

Vogt's limbal girdle

O3:

Keratoglobus

O4:

Corneal dystrophy

Ans: 1

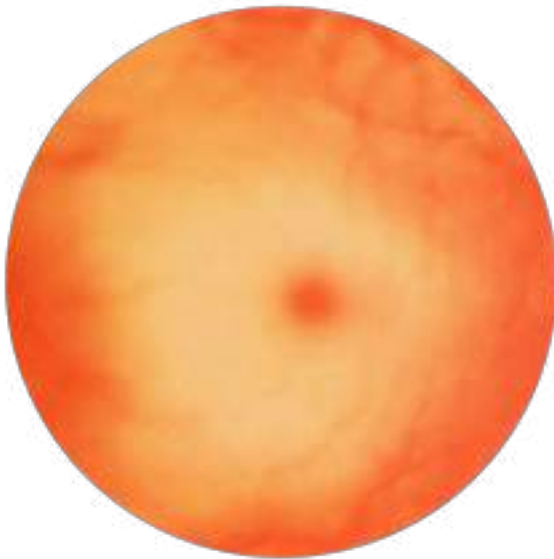
Ques No: 53

Subject: Ophthalmology

Topic: Retina

Sub-Topic:

A 3-year-old boy presents with mental retardation and an inability to walk. The fundoscopy image is given below. What is the most likely diagnosis?



O1:

Tay-Sachs disease

O2:

Hunter disease

O3:

Hurler syndrome

O4:

Gaucher disease

Ans: 1

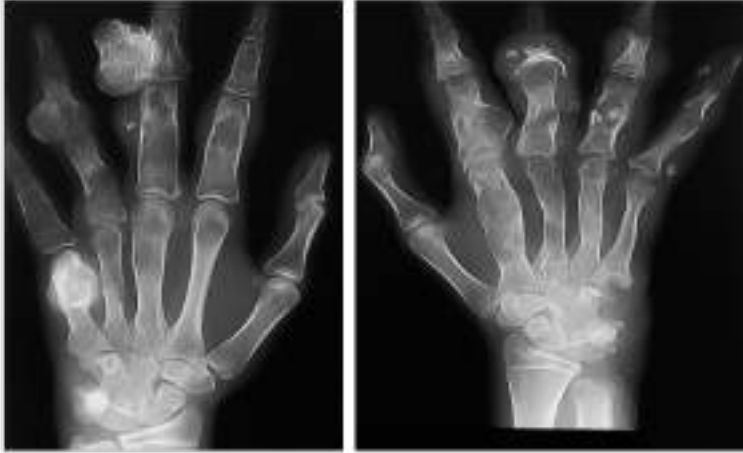Ques No: 54

Subject: Orthopaedics

Topic: Orthopedics Oncology

Sub-Topic:

What could be the diagnosis of a woman with this appearance on X-ray?



O1:

A multiple brown tumor

O2:

Fibrous dysplasia

O3:

Multiple enchondromas

O4:

Multiple exostoses

Ans: 3

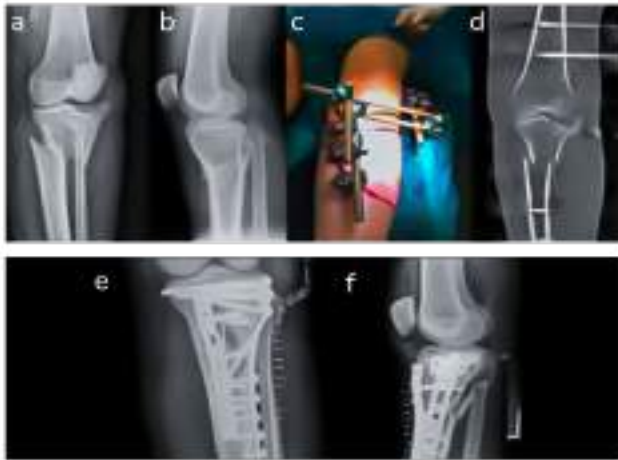Ques No: 55

Subject: Orthopaedics

Topic: Miscellaneous

Sub-Topic:

Which of the following is true about the type of fixation shown in the image?



O1:

Fracture tibia, ilizarov fixator

O2:

Fracture tibia, spanning fixator

O3:

Fracture femur, spanning fixator

O4:

Periarticular fracture of knee, spanning fixator

Ans: 4

Ques No: 56

Subject: Orthopaedics

Topic: Spine + Pelvis + Lower Limb Traumatology

Sub-Topic:

A male patient presented with a bone fracture following a road traffic accident. After 2 days he developed dyspnea, petechiae involving the whole body, and a fall in oxygen saturation. What is the likely diagnosis?

O1:

Fat embolism

O2:

Air embolism

O3:

Venous thromboembolism

O4:

Pulmonary hypertension

Ans: 1

Ques No: 57

Subject: Orthopaedics

Topic: Metabolic Disorders

Sub-Topic:

An intrauterine scan at the 13th week of pregnancy showed a fetus with multiple long bone fractures. What is commonly associated with this finding ?

O1:

Achondroplasia

O2:

Osteogenesis imperfecta

O3:

Cretinism

O4:

Marfan syndrome

Ans: 2

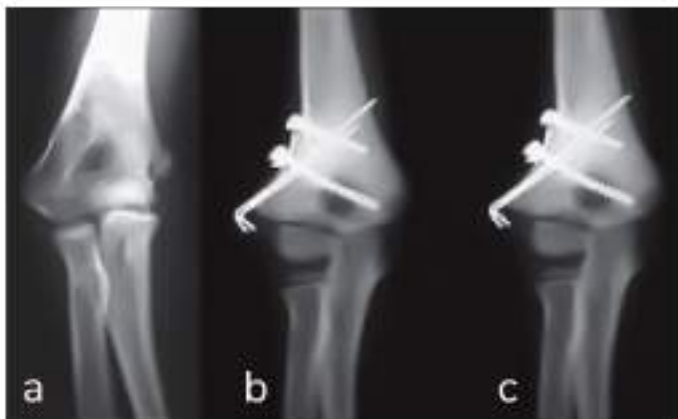Ques No: 58

Subject: Orthopaedics

Topic: Pediatric Orthopedics

Sub-Topic:

What is the most common complication of this condition, if left untreated ?



O1:

Malunion and stiffness

O2:

Non-union and cubitus varus

O3:

Cubitus valgus

O4:

Myositis ossificans

Ans: 3

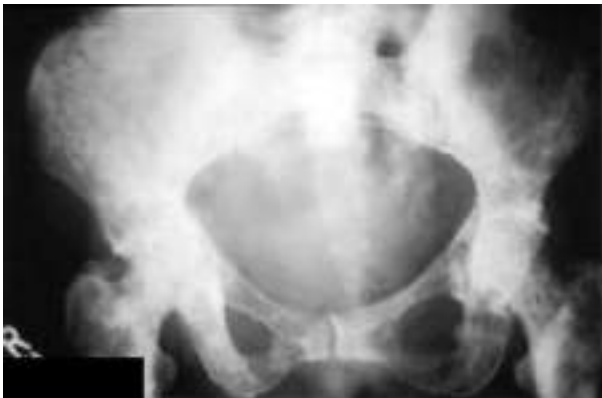Ques No: 59

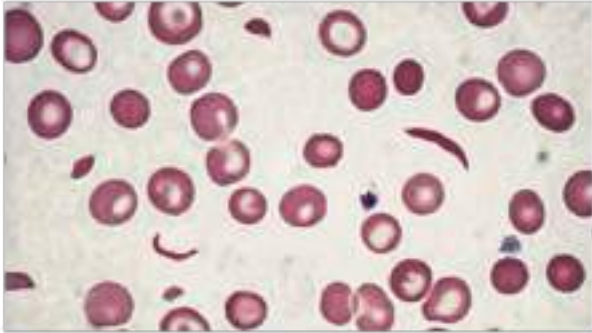
Subject: Orthopaedics

Topic: Bone and Joint Infections

Sub-Topic:

A child with a history of recurrent respiratory infections presented with complaints of pain around the knee and a high fever. X – ray shows lytic and sclerotic bone. His peripheral blood smear is shown in the image below. Aspirate from the joint will most likely show:





O1:
Staphylococcus aureus

O2:
Escherichia

O3:
Salmonella

O4:
Streptococcus

Ans: 3

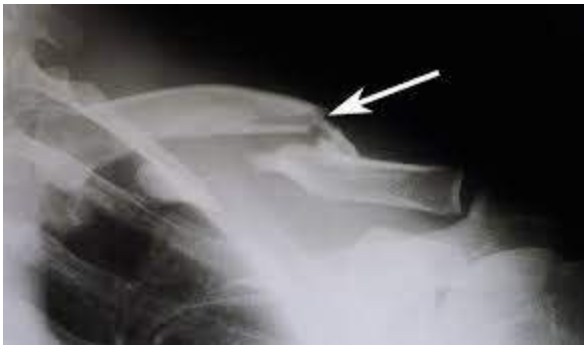Ques No: 60

Subject: Orthopaedics

Topic: General + Upper Limb Traumatology

Sub-Topic:

A boy falls on the left shoulder joint and presents to the emergency department with shoulder pain. His left elbow is flexed and is supported by the right hand. Which bone might be most likely fractured?



O1:

1

O2:

2

O3:

3

O4:

4

Ans: 1

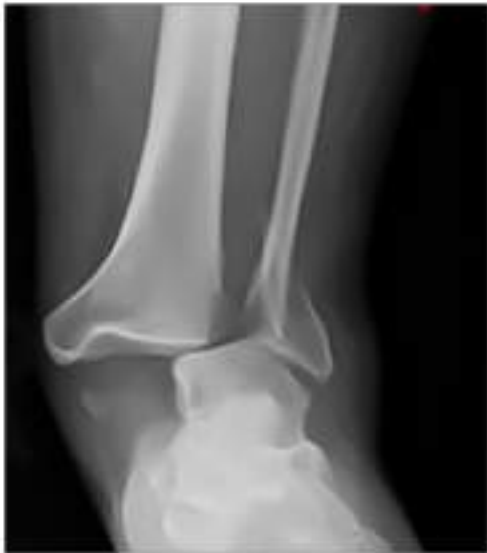Ques No: 61

Subject: Orthopaedics

Topic: Spine + Pelvis + Lower Limb Traumatology

Sub-Topic:

An RTA patient presented to the emergency department with severe pain in the Ankle, an X ray was performed, given below. What is the best next step of management?



O1:

Neurovascular Assessment and Closed reduction and slab application

O2:

Neurovascular Assessment and Closed reduction and cast application

O3:

Neurovascular Assessments and Immediate surgery

O4:

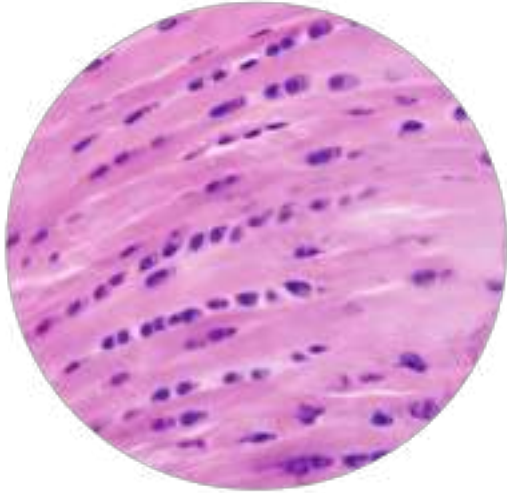
Neurovascular Assessments and Immediate open reduction

Ans: 1

Ques No: 62

Subject: Anatomy
Topic: Histology
Sub-Topic:

Identify the cartilage given below?



O1:
Non-articular hyaline cartilage

O2:
Articular hyaline cartilage

O3:
Yellow cartilage

O4:
White fibrocartilage

Ans: 4

Ques No: 63

Subject: Pathology
Topic: Cell Injury
Sub-Topic:

Choose the correct statement regarding the telomerase theory of aging

O1:
Telomere stability is associated with aging

O2:
Abnormal telomerase activation is associated with aging

O3:
Decreased telomere length is associated with aging

O4:
Increased telomere length is associated with aging

Ans: 3

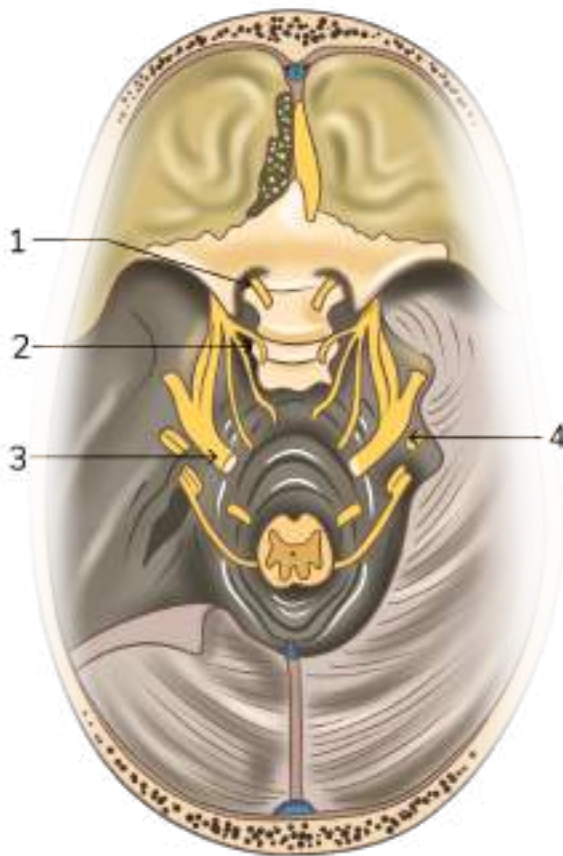
Ques No: 64

Subject: Anatomy

Topic: Head and Neck

Sub-Topic:

A patient presents with a unilateral throbbing headache, photophobia, and excessive lacrimation. He also complains of hemifacial pain on the clenching of teeth. On examination, pupillary reaction, light reflex, and accommodation reflex are normal. Which of the following marked nerves is involved in the above scenario?



O1:

1

O2:

2

O3:

3

O4:

4

Ans: 3

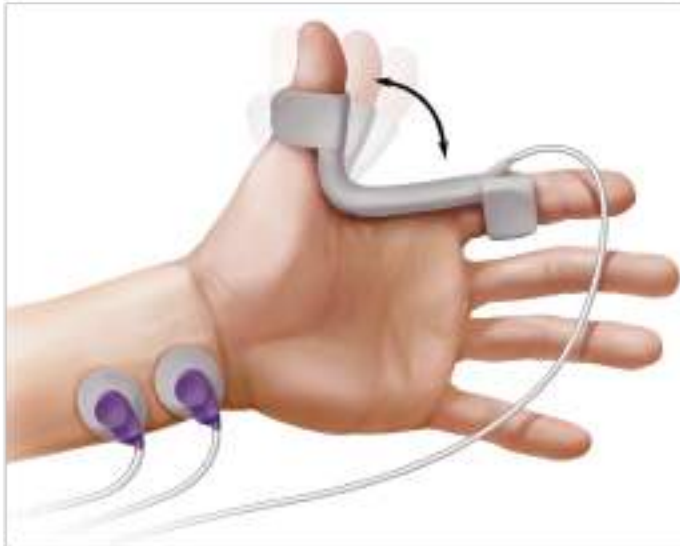
Ques No: 65

Subject: Anaesthesia

Topic: Neuromuscular Blockade

Sub-Topic:

The image given below shows neuromuscular monitoring of the patient after anesthesia. What is the most commonly used nerve for monitoring?



O1:
Ulnar nerve

O2:
Median nerve

O3:
Radial nerve

O4:
Metacarpal nerve

Ans: 1

Ques No: 66

Subject: Biochemistry

Topic: Genetics

Sub-Topic:

Which of the following disorders follows autosomal recessive inheritance pattern?

O1:
Huntington's disease

O2:

Treacher collins syndrome

O3:

Cystic fibrosis

O4:

Achondroplasia

Ans: 3

Ques No: 67

Subject: Biochemistry

Topic: Lipid Metabolism

Sub-Topic:

Which of the following helps in the transport of fatty acids across the inner mitochondrial membrane?

O1:

Acyl carrier protein

O2:

Carnitine

O3:

Lecithin-cholesterol acyltransferase

O4:

Carnitine and albumin

Ans: 2

Ques No: 68

Subject: Biochemistry

Topic: Genetics

Sub-Topic:

A single mutation in a nucleotide base pair resulting in a termination codon is known as _____?

O1:

Missense mutation

O2:

Nonsense mutation

O3:

Stop mutation

O4:

Silent mutation

Ans: 2

Ques No: 69

Subject: Biochemistry

Topic: Introduction

Sub-Topic:

DNA packing is done by which of the following?

O1:

Histone

O2:

Glycoprotein

O3:

Nucleic acid

O4:

Adenine

Ans: 1

Ques No: 70

Subject: Biochemistry

Topic: Carbohydrate Metabolism

Sub-Topic:

An adolescent male patient presents to you with exercise intolerance. He gives a history of developing cramps on exertion. Which of the following enzyme deficiencies could be the cause?

O1:

Myophosphorylase

O2:

Hexokinase

O3:

Glucose-6-phosphatase

O4:

Hepatic glycogen phosphorylase

Ans: 1

Ques No: 71

Subject: Biochemistry

Topic: Vitamins

Sub-Topic:

Which of the following enzyme activities can be estimated in red blood cells to diagnose vitamin B2 deficiency?

O1:

Transketolase

O2:

Glutathione reductase

O3:

Kynureninase

O4:

Pyruvate dehydrogenase

Ans: 2

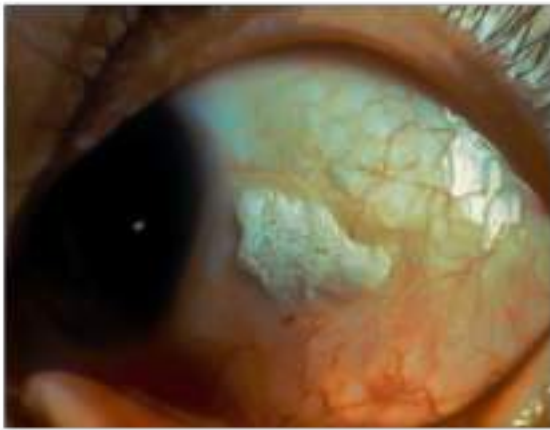
Ques No: 72

Subject: Biochemistry

Topic: Vitamins

Sub-Topic:

The following is due to the deficiency of?



O1:

Vitamin C

O2:

Vitamin A

O3:

Vitamin B

O4:

Vitamin E

Ans: 2

Ques No: 73

Subject: Biochemistry

Topic: Carbohydrate Metabolism

Sub-Topic:

A child presents to you with anemia, thrombocytopenia, and bony pain. On examination, hepatosplenomegaly was noticed. If light microscopy of bone marrow aspirate reveals "crumpled tissue paper" appearance, what is the enzyme defect?

O1:
Glucocerebrosidase

O2:
Sphingomyelinase

O3:
Hexosaminidase

O4:
Glucose6-phosphatase

Ans: 1

Ques No: 74

Subject: Biochemistry

Topic: Oxidative Phosphorylation

Sub-Topic:

The electron transport chain is a series of redox reactions that result in ATP synthesis. Which of the following is a cytochrome complex IV inhibitor?

O1:
Cyanide

O2:
Carbon dioxide

O3:
Oligomycin

O4:
Ouabain

Ans: 1

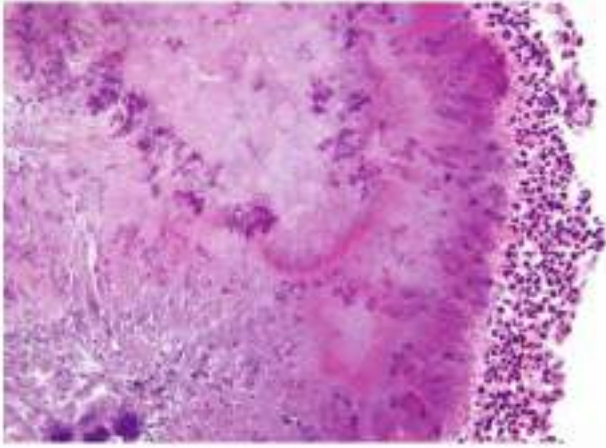
Ques No: 75

Subject: Dermatology

Topic: Cutaneous Infections

Sub-Topic:

A farmer presents to you with swelling on foot and multiple discharging sinuses in the lower limb. Granules from the discharge were examined under the microscope, shown below. Which of the following is true regarding this condition?



O1:
Both bacteria and fungi can be causative

O2:
Undergoes lymphatic spread

O3:
There is lymphocyte accumulation

O4:
Involves only superficial tissues

Ans: 1

Ques No: 76

Subject: Dermatology

Topic: Cutaneous Infections

Sub-Topic:

A farmer presents you with a cauliflower-shaped mass on foot, which developed after a minor injury. Microscopy shows copper penny bodies. What is the most likely diagnosis?

O1:
Chromoblastomycosis

O2:
Blastomycosis

O3:
Sporotrichosis

O4:
Phaeohyphomycosis

Ans: 1

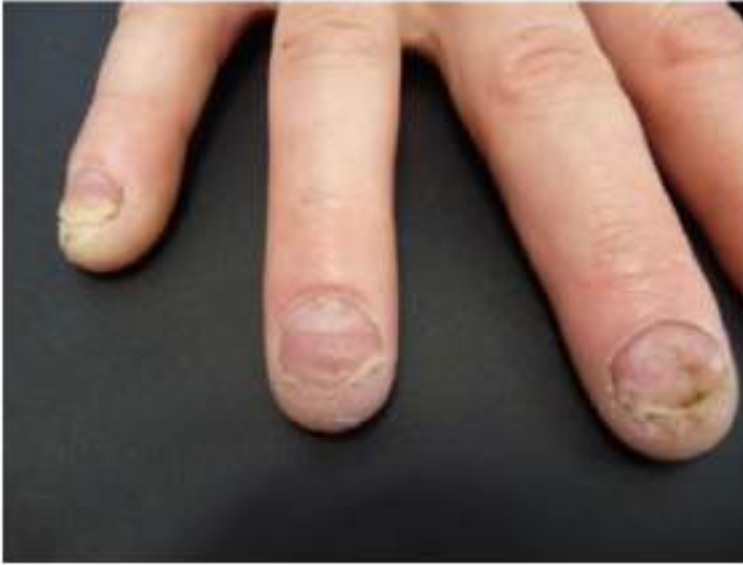Ques No: 77

Subject: Dermatology

Topic: Skin Appendages and their Disorders

Sub-Topic:

Irregular pitting of nails with subungual hyperkeratosis is seen in _____.



O1:
Lichen planus

O2:
Psoriasis

O3:
Atopic dermatitis

O4:
Alopecia areata

Ans: 2

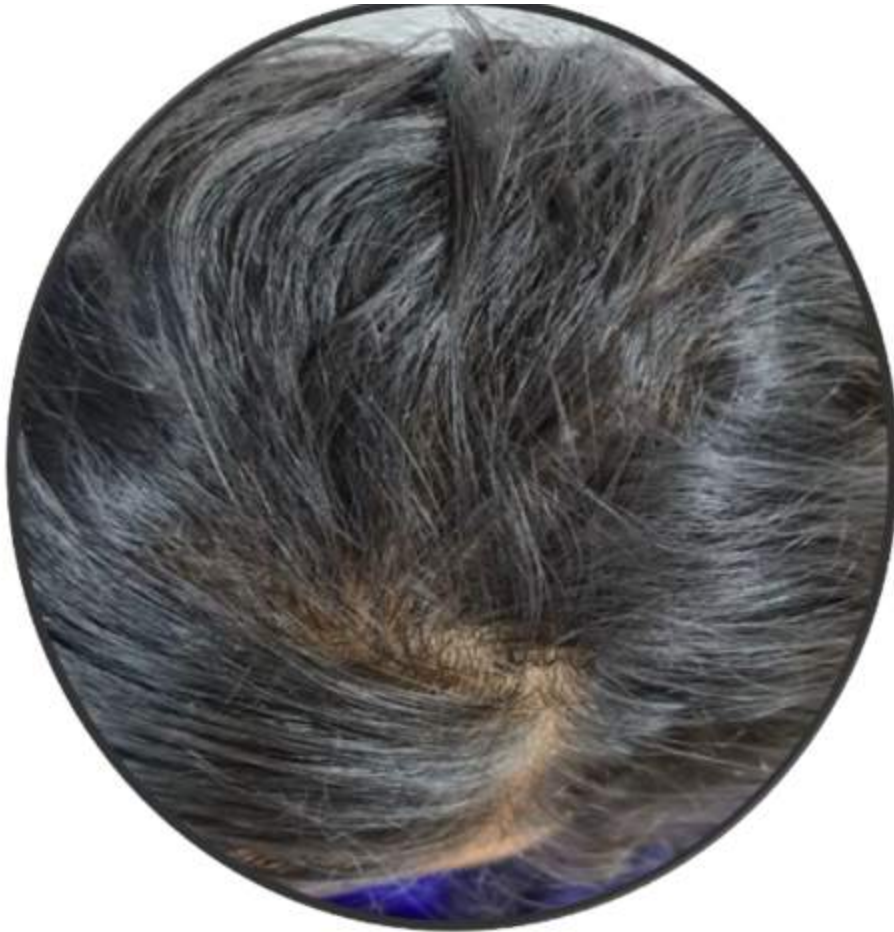Ques No: 78

Subject: Dermatology

Topic: Skin Appendages and their Disorders

Sub-Topic:

A 35-year-old woman presents to you with hair loss for the past three months. She tested positive for COVID-19 eight months ago. What is the most likely diagnosis?



O1:
Tinea capitis

O2:
Telogen effluvium

O3:
Trichotillomania

O4:
Female – pattern androgenic alopecia

Ans: 2

Ques No: 79

Subject: ENT

Topic: Nose and Paranasal Sinuses

Sub-Topic:

A post-COVID patient, who is a known diabetic, develops unilateral facial pain and loosening of teeth. Which investigation would you do to confirm the diagnosis of this patient?

O1:
MRI

O2:

Biopsy with histopathologic examination

O3:
Serum ferritin

O4:
HbA1c

Ans: 2

Ques No: 80

Subject: ENT

Topic: Ear

Sub-Topic:

A patient presents with the complaint of inability to close the eye, drooling of saliva, and deviation of the angle of the mouth. Which of the following nerves is most likely to be affected?

O1:
Facial nerve

O2:
Trigeminal nerve

O3:
Oculomotor nerve

O4:
Glossopharyngeal nerve

Ans: 1

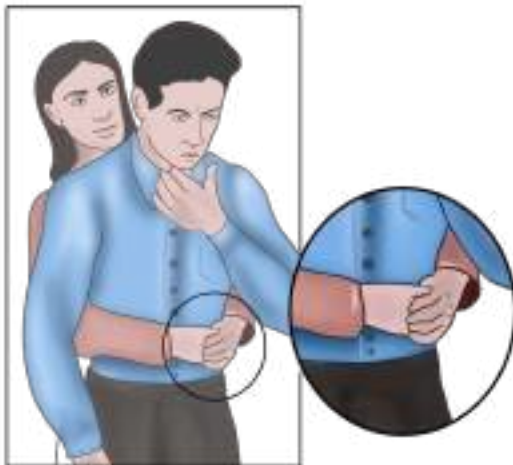
Ques No: 81

Subject: ENT

Topic: Pharynx

Sub-Topic:

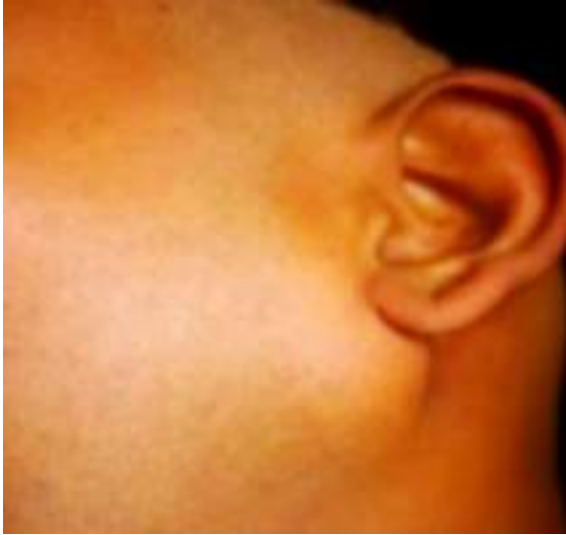An adult man in a restaurant suddenly begins choking on his food. He is conscious. The following procedure was performed. Identify the procedure.



O1: Heimlich's maneuver
O2: Back slap
O3: Chest thrust
O4: Blind insertion of finger
Ans: 1

Ques No: 82 Subject: Pathology Topic: Hematology: Red Blood Cells Sub-Topic: A child presents with recurrent chest infections and abdominal pain. There is a history of 1 blood transfusion in the past. On examination, he had icterus and mild splenomegaly. Electrophoresis shows increased HbA2, HbF, and S spike. What is the likely diagnosis?
O1: Beta thalassemia
O2: HbC disease
O3: Sickle cell disease
O4: Acute coronary disease
Ans: 1

Ques No: 83 Subject: ENT Topic: Pharynx Sub-Topic: A patient presents with a firm, tender, slow-growing mass below the ear as shown in the image below. What could be the diagnosis?



O1:
Bezold abscess

O2:
Parotid abscess

O3:
Upper cervical lymphadenopathy

O4:
Osteoma of the mandible

Ans: 2

Ques No: 84

Subject: ENT

Topic: Nose and Paranasal Sinuses

Sub-Topic:

A patient comes with a history of asthma and sinusitis. On looking into his medical records, you notice this has been attributed to Samter's triad. Which drug should be avoided in this patient?

O1:
Cotrimoxazole

O2:
Co-amoxiclav

O3:
Aspirin

O4:
Chloramphenicol

Ans: 3

Ques No: 85

Subject: Pathology

Topic: Neoplasia

Sub-Topic:

Why do neoplastic cells utilize Warburg metabolism?

O1:

It decreases glucose utilization by neoplastic cells

O2:

It forms metabolic intermediates which are needed for cell growth and multiplication

O3:

It provides more energy in the form of increased ATP production

O4:

It prevents apoptosis and makes the cancer immortal

Ans: 2

Ques No: 86

Subject: ENT

Topic: Ear

Sub-Topic:

A 70-year-old male patient presents with decreased hearing in higher frequencies. It was noted that the basilar membrane was affected. Which of the following structures lie near the affected structure?

O1:

Modiolus

O2:

Stria vascularis

O3:

Oval window

O4:

Helicotrema

Ans: 3

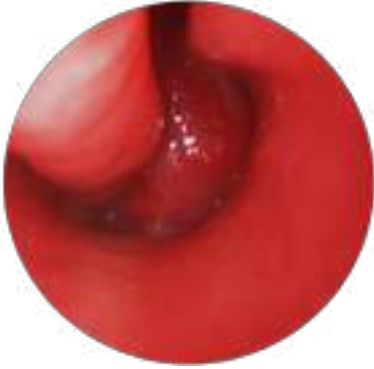Ques No: 87

Subject: ENT

Topic: Pharynx

Sub-Topic:

A 20-year-old male patient presents with unilateral nasal obstruction and recurrent bleeding for the past 1 year. Transnasal endoscopic results are shown below. A contrast – enhanced CT revealed a mass extending from the posterior choana to the nasopharynx. What is the most likely diagnosis?



O1:
Nasopharyngeal angiofibroma

O2:
Antrochoanal polyp

O3:
Rhinoscleroma

O4:
Concha bullosa

Ans: 1

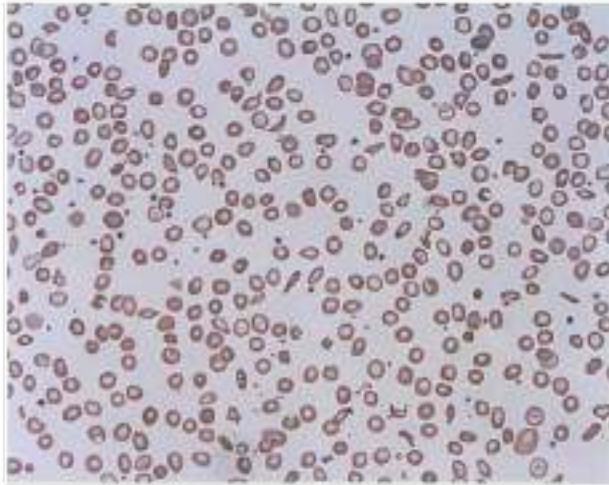
Ques No: 88

Subject: Pathology

Topic: Hematology: Red Blood Cells

Sub-Topic:

An elderly patient presents with anemia and hemoglobinuria. Investigations reveal increased lactate dehydrogenase (LDH). The peripheral smear image is given below. Which of the following physical examination findings can support the likely diagnosis?



O1:
Splenomegaly

O2:
Frontal bossing

O3:
Mechanical second heart sound

O4:
Goitre

Ans: 1

Ques No: 89

Subject: Pathology

Topic: Hematology: White Blood Cells

Sub-Topic:

All of the following statements are true regarding neutrophil extracellular trapping (NET) except that

O1:
It is detected in blood during sepsis

O2:
It is produced in response to bacterial infection

O3:
Mitochondrial DNA is seen

O4:
It is chromatin with antibacterial enzymes

Ans: 3

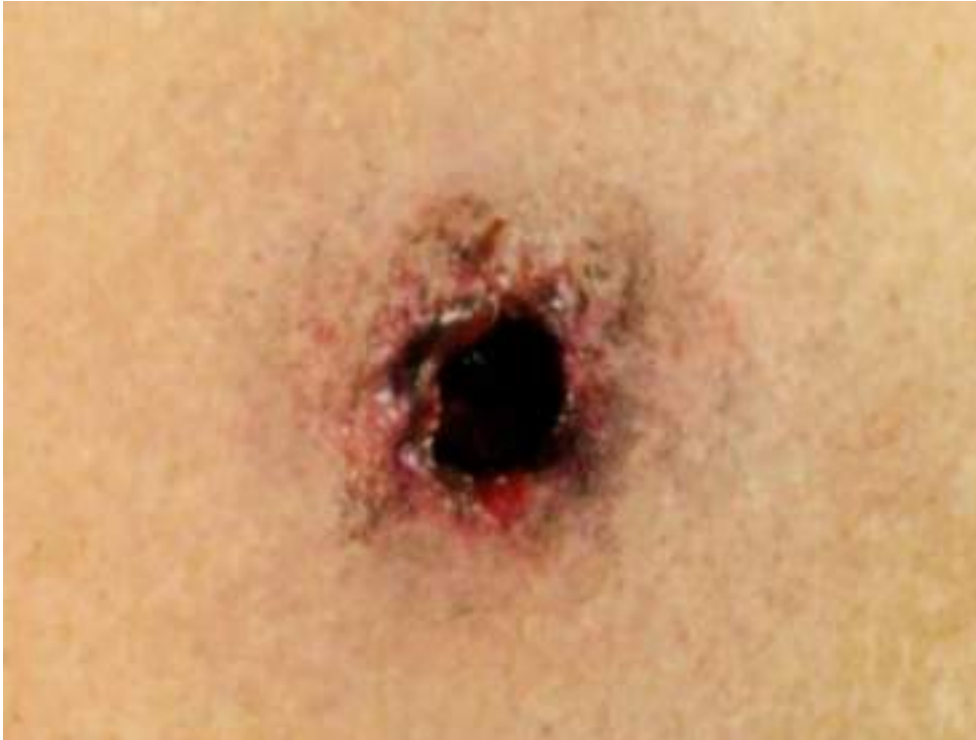
Ques No: 90

Subject: Forensic Medicine

Topic: Ballistics

Sub-Topic:

Identify the gun that caused the wound and the range of the shot.



O1:

Shotgun, intermediate range

O2:

Shotgun, close range

O3:

Pistol, near shot

O4:

Pistol, close shot

Ans: 3

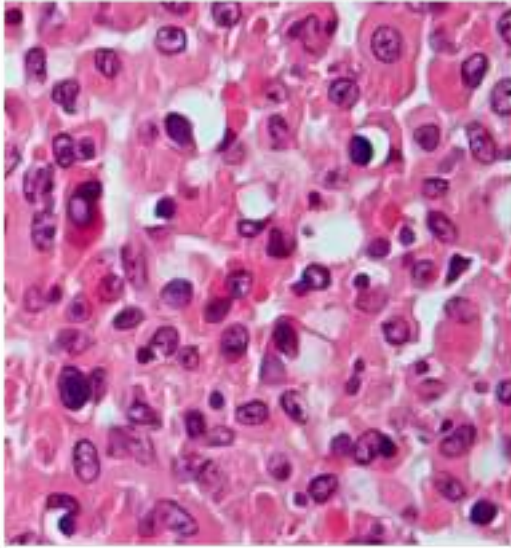
Ques No: 91

Subject: Pathology

Topic: Renal System

Sub-Topic:

A patient underwent cystoscopy, which showed multiple yellow-white plaques in the trigone of the bladder. The histopathology image is given below. What is the diagnosis?



O1:
Interstitial cystitis

O2:
Malakoplakia

O3:
Polypoid cystitis

O4:
Acute cystitis

Ans: 2

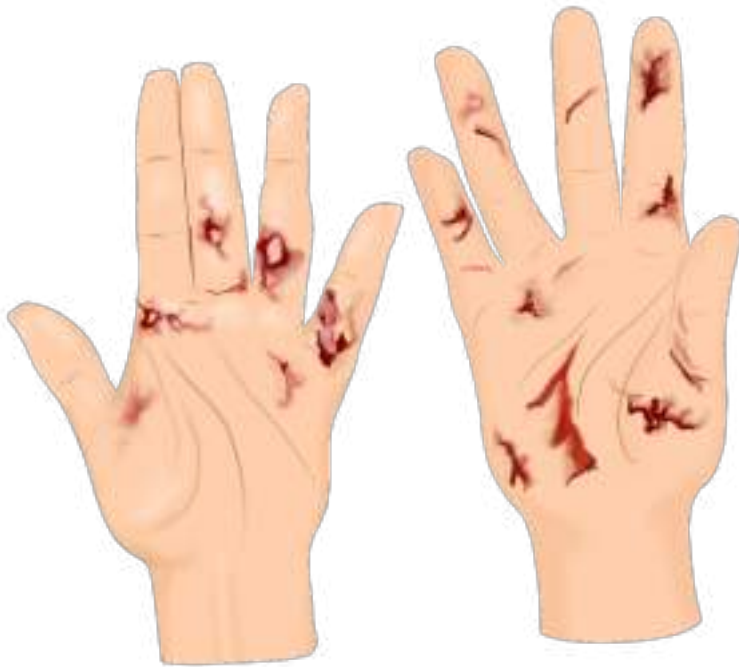Ques No: 92

Subject: Forensic Medicine

Topic: Forensic Traumatology

Sub-Topic:

Identify the type of wound from the image.



O1:
Defense wounds

O2:
Antemortem wound

O3:
Postmortem wound

O4:
Hesitation cuts

Ans: 1

Ques No: 93

Subject: Pathology

Topic: Cell Injury

Sub-Topic:

Which of the following measures are associated with an increased life span?

O1:
Moderate of regular exercise for 30 min

O2:
Decrease stress

O3:
Decreasing calorie intake by 30 percent

O4:
Pharmacological intervention with proton pump inhibitors

Ans: 3

Ques No: 94

Subject: Forensic Medicine

Topic: Court of Law

Sub-Topic:

A 45-year-old female patient is told about the benefits and complications of a hysterectomy, and she agrees to the procedure. What kind of consent is this?

O1:

Informed consent

O2:

Implied consent

O3:

Opt-out

O4:

Passive consent

Ans: 1

Ques No: 95

Subject: Pathology

Topic: Respiratory System

Sub-Topic:

A 56-year-old man was diagnosed with COVID-19 and was put on mechanical ventilation. He passed away after a week. What is the likely post-mortem change seen in the lungs?

O1:

Thick layer of fibrin lining the alveoli

O2:

Acute and chronic alveolar hemorrhage

O3:

Perivascular cuffing

O4:

Pulmonary artery hypertrophy with increased resistance

Ans: 2

Ques No: 96

Subject: Forensic Medicine

Topic: Asphyxial Deaths

Sub-Topic:

A dead body is brought for evaluation. On post-mortem examination, a ligature completely encircled the neck, horizontal, and below the thyroid level was seen. There was no dribbling of saliva. What is the cause of death?

O1:

Throttling
O2: Ligature strangulation
O3: Gagging
O4: Hanging
Ans: 2

<p>Ques No: 97 Subject: Forensic Medicine Topic: IPC Sections Sub-Topic:</p> <p>A surgeon returns home from a party after many pegs of alcohol and is called to perform an emergency operation. During the operation, the assisting staff noticed the surgeon's handshaking and the instruments falling. He eventually nicks an artery, and the patient collapses. Under which of the following terms will this incident be tried?</p>
O1: Criminal negligence
O2: Civil negligence not amounting to criminal negligence
O3: Therapeutic misadventure
O4: Dichotomy
Ans: 1

<p>Ques No: 98 Subject: Forensic Medicine Topic: Court of Law Sub-Topic:</p> <p>During the court proceedings, the defense lawyer asks a leading question, which the prosecutor appeals against. The judge grants the appeal. Leading questions are not allowed in all of the following except?</p>
O1: Re-examination
O2: Cross-examination
O3: Examination in chief
O4: Dying declaration

Ans: 2

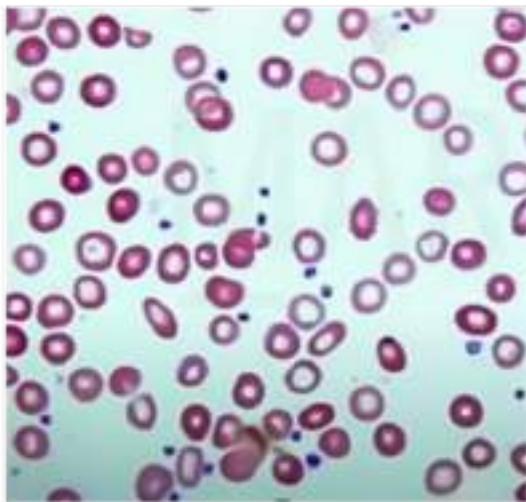
Ques No: 99

Subject: Pathology

Topic: Hematology: Red Blood Cells

Sub-Topic:

A female patient presented with fatigue and a history of piles. Routine complete blood count analysis showed hemoglobin of 9 g/dL, MCV 60fL, and RBC count of 5.2 million. A peripheral smear is given below. Which of the following is the next best investigation for this patient?



O1:
HbA2 levels

O2:
Serum ferritin levels

O3:
Serum folate levels

O4:
Serum homocysteine levels

Ans: 2

Ques No: 100

Subject: Pathology

Topic: Hematology: White Blood Cells

Sub-Topic:

A 56-year-old man presents with dragging pain in the abdomen. On examination, there is massive splenomegaly. Peripheral smear shows leukocytosis with increased myelocytes, metamyelocytes and basophils. Which of the following translocations is seen in this condition?

O1:

t(9;22)
O2: t(8;22)
O3: t(15;17)
O4: t(8;14)
Ans: 1

<p>Ques No: 101 Subject: Medicine Topic: Endocrinology Sub-Topic:</p> <p>A patient with diabetes mellitus for the past 5 years presents with vomiting and abdominal pain. She is non-compliant with medication and appears dehydrated. Investigations revealed a blood sugar value of 500 mg/dl and the presence of ketone bodies. What is the next best step in management?</p>
O1: Intravenous fluids with long-acting insulin
O2: Intravenous fluids
O3: Intravenous insulin
O4: Intravenous fluids with regular insulin
Ans: 4

<p>Ques No: 102 Subject: Medicine Topic: Infections Sub-Topic:</p> <p>A patient diagnosed to be retro-positive was started on highly active antiretroviral therapy (HAART). Which of the following can be used to monitor treatment efficacy?</p>
O1: CD4+ T cell count
O2: Viral load
O3: p24 antigen
O4: Viral serotype
Ans: 2

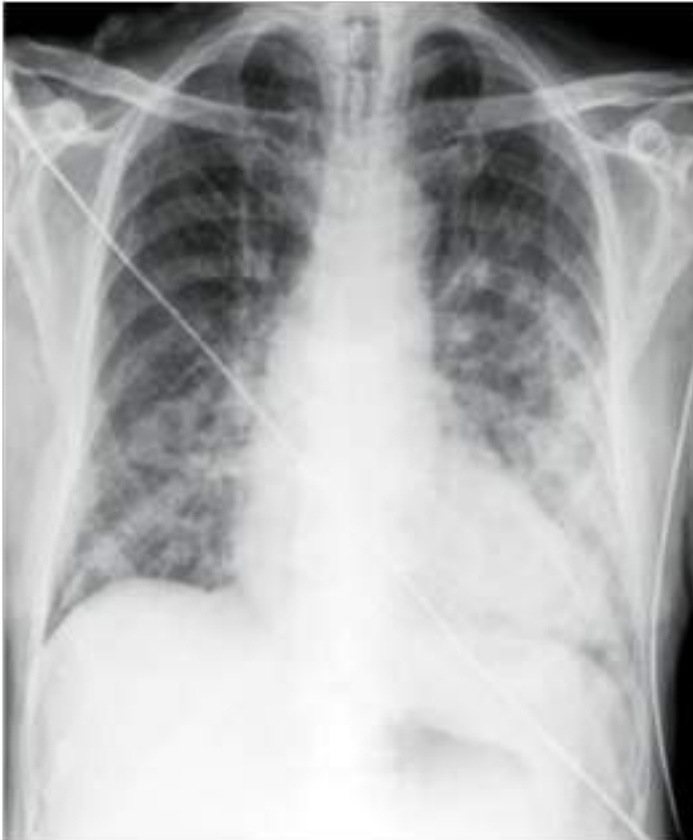Ques No: 103

Subject: Medicine

Topic: Cardiology

Sub-Topic:

A hypertensive patient who is non-compliant with medication presents to you with sudden onset breathlessness. A chest x-ray was done, which is shown below. How will you manage this patient?



O1:

Intravenous salbutamol

O2:

Intravenous nitro-glycerine

O3:

Nebulization with salbutamol

O4:

Oxygen and antibiotics

Ans: 2

Ques No: 104

Subject: Pediatrics

Topic: Neonatology

Sub-Topic:

A 1 day- old neonate has not passed urine since birth. What is the next step in management?

O1:

a.Continue breast feeding not observed

O2:

Admit to NICU'

O3:

Start artificial feeding

O4:

Start intravenous fluids

Ans: 1

Ques No: 105

Subject: Medicine

Topic: Cardiology

Sub-Topic:

A patient on anti-depressants presented to you with hypotension. An ECG was done, which showed wide QRS complexes and right axis deviation. How will you manage this patient?

O1:

Antiarrhythmics

O2:

Intravenous sodium bicarbonate

O3:

Propranolol

O4:

Phenytoin

Ans: 2

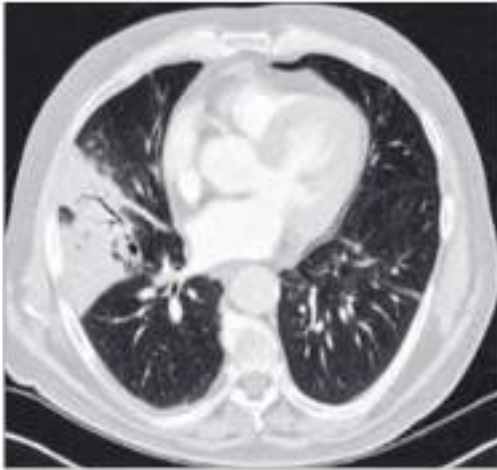Ques No: 106

Subject: Medicine

Topic: Pulmonology

Sub-Topic:

A 35-year-old female patient presents to you with fever, breathlessness, and cough with expectoration. A CT scan was done which is shown below. What is the most likely diagnosis?



O1:
Consolidation with air bronchogram

O2:
Mediastinal mass

O3:
Pleural effusion

O4:
Diaphragmatic hernia

Ans: 1

Ques No: 107

Subject: Pediatrics

Topic: Fluid and Electrolyte Disturbances

Sub-Topic:

A 7 – year old boy presented with abdominal pain, vomiting, oliguria, and periorbital puffiness following chemotherapy. Investigations reveal hyperuricemia, raised creatinine levels, and hyperkalemia. What is the next best step in the management of this condition ?

O1:
Hydration

O2:
Probenecid

O3:
Allopurinol

O4:
Rasburicase

Ans: 1

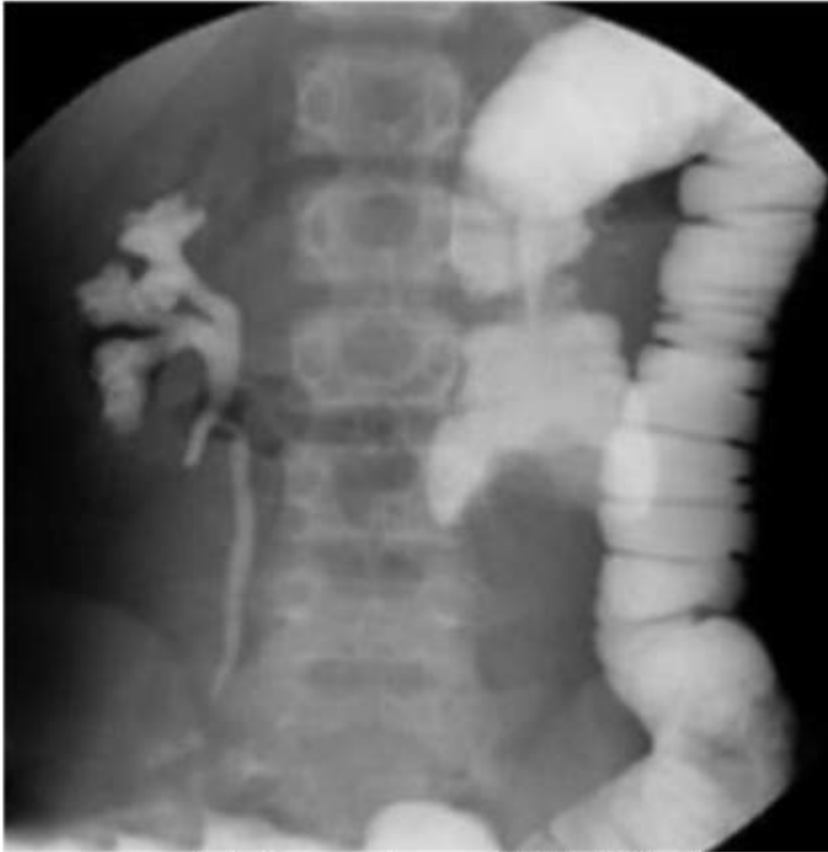Ques No: 108

Subject: Pediatrics

Topic: Pediatric Gastroenterology

Sub-Topic:

A baby presented with abdominal pain. On examination, a mass is palpated in the right lumbar region. A barium enema is done, and the image is given below. What is the likely diagnosis?



O1:
Intussusception

O2:
Volvulus

O3:
Duodenal atresia

O4:
Intestinal obstruction

Ans: 1

Ques No: 109

Subject: Medicine

Topic: Neurology

Sub-Topic:

A female patient with a negative urine pregnancy test presents to you with galactorrhea. An MRI was done which revealed a large pituitary tumor. If the patient is not willing for surgery,

which of the following is the best drug for treatment?
O1: Bromocriptine
O2: Promethazine
O3: Octreotide
O4: Clozapine
Ans: 1

<p>Ques No: 110 Subject: Medicine Topic: Nephrology / Kidney Disease Sub-Topic:</p> <p>A woman presents to you with fever, arthralgia, ulcers, fatigue for the past six months, and new-onset hematuria. Urine examination reveals RBC casts and proteinuria. What is the likely diagnosis?</p>
O1: Acute interstitial nephritis
O2: Poststreptococcal glomerulonephritis
O3: Lupus nephritis
O4: IgA nephropathy
Ans: 3

<p>Ques No: 111 Subject: Medicine Topic: Nephrology / Kidney Disease Sub-Topic:</p> <p>A man on diuretics presents with weakness. An ECG was done which showed flat T waves and prominent U waves. What is the most likely diagnosis?</p>
O1: Hypokalaemia
O2: Hyperkalaemia
O3: Hypomagnesemia
O4: Hypernatremia

Ans: 1

Ques No: 112

Subject: Medicine

Topic: Nephrology / Kidney Disease

Sub-Topic:

A male patient presents to the emergency department. The arterial blood gas report is as follows: pH, 7.2; pCO₂, 81 mmHg; and HCO₃, 40meq/L. which of the following is the most likely diagnosis?

O1:

Respiratory alkalosis

O2:

Metabolic acidosis

O3:

Respiratory acidosis

O4:

Metabolic alkalosis

Ans: 3

Ques No: 113

Subject: Medicine

Topic: Pulmonology

Sub-Topic:

Multidrug-resistant (MDR) tuberculosis shows resistance to which of the following drugs?

O1:

Isoniazid, rifampicin, and fluoroquinolone

O2:

Fluoroquinolones

O3:

Isoniazid and rifampicin

O4:

Isoniazid, rifampicin, and kanamycin

Ans: 3

Ques No: 114

Subject: Medicine

Topic: Liver

Sub-Topic:

A patient presents to you with a fever, jaundice, and malaise. What is the most likely diagnosis based on the serology reports given below?

Anti-HBc (IgM): Positive

HBsAg: Positive

Anti-HBs: Negative Anti-HCV antibodies: Negative
O1: Acute hepatitis B
O2: Acute hepatitis C
O3: Chronic hepatitis B
O4: Chronic hepatitis C
Ans: 1

<p>Ques No: 115 Subject: Medicine Topic: Liver Sub-Topic:</p> <p>A child presents to the emergency department with a history of ingestion of 10-20 ferrous sulphate tablets. Arterial blood gas revealed acidosis. Which of the following can be used in the management of this condition?</p>
O1: Deferoxamine
O2: Activated charcoal
O3: Dimercaprol
O4: Penicillamine
Ans: 1

<p>Ques No: 116 Subject: Microbiology Topic: Immunology Sub-Topic:</p> <p>A photographer who recently returned from Africa presents to the emergency department with abdominal pain, hepatomegaly, and hemorrhagic manifestations. He died despite treatment, and an autopsy revealed intranuclear Torres bodies in the liver. Which of the following vaccines with which strain could have prevented it?</p>
O1: 17D
O2: Nakayama vaccine
O3: Weigl's vaccine

O4:

Jeryl Lynn strain

Ans: 1

Ques No: 117

Subject: Microbiology

Topic: Systemic Bacteriology

Sub-Topic:

A militant presents with rashes all over his body sparing the palms and soles. On examination, he was febrile and lice were noted. Which of the following is responsible for his condition?

O1:

Rickettsia typhi

O2:

Rickettsia prowazekii

O3:

Rickettsia akari

O4:

Rickettsia conorii

Ans: 2

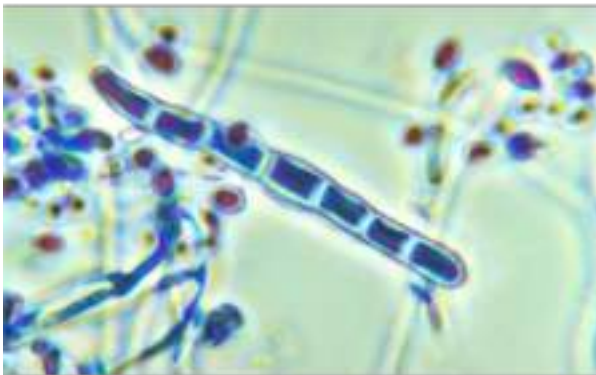
Ques No: 118

Subject: Microbiology

Topic: Mycology

Sub-Topic:

A patient presents with itching in the axilla. On microscopic examination of the skin scrapings, a red pigment-producing fungus with pencil – shaped macroconidia is seen. Which of the following is the most likely organism?



O1:

Trichophyton violaceum

O2:

Trichophyton rubrum

O3:

Trichophyton tonsurans

O4:

Trichophyton schoenleinii

Ans: 2

Ques No: 119

Subject: Microbiology

Topic: Mycology

Sub-Topic:

A female patient presents with complaints of thick white vaginal secretions. Which of the following can be used to identify the likely species of the causative agent?

O1:

Birds seed agar

O2:

Brain heart infusion agar

O3:

CHRO Magar

O4:

Sabouraud dextrose agar

Ans: 3

Ques No: 120

Subject: Microbiology

Topic: Mycology

Sub-Topic:

A 12-year-old boy presents with right upper quadrant pain, calf pain, conjunctival suffusion, icterus, and fever. Examination shows tender hepatomegaly. What is the most likely diagnosis?

O1:

Chikungunya

O2:

Leptospirosis

O3:

Dengue hemorrhagic fever

O4:

Encephalopathy caused by hepatitis A

Ans: 2

Ques No: 121

Subject: Microbiology

Topic: Systemic Bacteriology

Sub-Topic:

A newly joined teacher develops rice water stools. The causative agent acts on which of the following receptors?

O1:

GM 1 ganglioside receptor

O2:

GM 2 ganglioside receptor

O3:

Sphingomyelin

O4:

Cerebroganglioside

Ans: 1

Ques No: 122

Subject: Microbiology**Topic:** Systemic Bacteriology**Sub-Topic:**

Which of the following is considered to be the best for the detection of *Clostridium difficile*?

O1:

Aerobic culture of stool

O2:

Glutamate dehydrogenase and toxin assay

O3:

Glutamate dehydrogenase assay

O4:

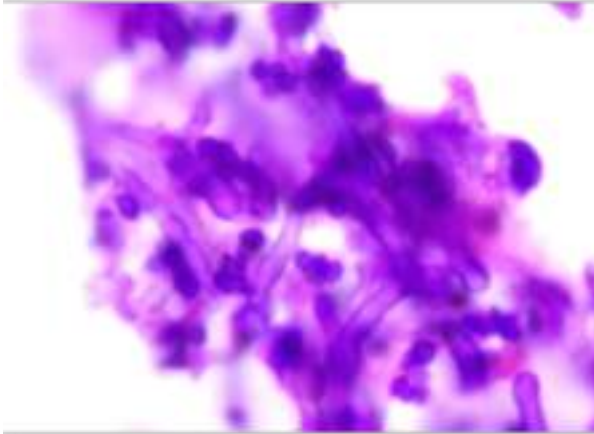
None of the above

Ans: 2

Ques No: 123

Subject: Microbiology**Topic:** Systemic Bacteriology**Sub-Topic:**

A diabetic truck driver presents to you with cough and breathlessness. A diagnosis of pneumonia was confirmed, and histopathological examination revealed dichotomous branching, as shown below. What is the likely causative agent?



O1:
Rhizopus

O2:
Mucor

O3:
Candida

O4:
Aspergillus

Ans: 2

Ques No: 124

Subject: Microbiology

Topic: Mycology

Sub-Topic:

A woman with recurrent diarrhea is prescribed a broad-spectrum antibiotic. Which of the following is not true regarding Clostridium difficile infection?

O1:
Oral fidaxomicin is used for treatment

O2:
It is toxin mediated

O3:
IgM assay is used to confirm the diagnosis

O4:
Pseudomembrane is a layer of inflammatory

Ans: 3

Ques No: 125

Subject: Pediatrics

Topic: Pediatric Endocrinology

Sub-Topic:

An 8-day old newborn was found to have a thyroid – stimulating hormone level of more than 100 mIU/L. Which of the following will be the next best investigation?

O1:

Urine iodine excretion

O2:

Serum thyroid receptor antibody

O3:

Radiotracer uptake with technetium

O4:

Perchlorate secretion

Ans: 3

Ques No: 126

Subject: Pediatrics

Topic: Pediatric Neurology

Sub-Topic:

A 10-month old infant was brought with complaints of jerking movement of limbs towards the body. On examination, there is a regression of developmental milestones.

Electroencephalogram shows hypsarrhythmia. Which of the following is the drug of choice in this condition ?

O1:

Phenytoin

O2:

Adrenocorticotrophic hormone

O3:

Levetiracetam

O4:

Phenobarbitone

Ans: 2

Ques No: 127

Subject: Pediatrics

Topic: Infectious Diseases

Sub-Topic:

A 2-month old infant born to an HIV- positive mother presents with recurrent diarrhea. What is the next best step?

O1:

Test stool for giardia and give antibiotics

O2:

Dried spot sample for HIV DNA PCR

O3:

Antibody test for HIV

O4:

Aerobic culture

Ans: 2

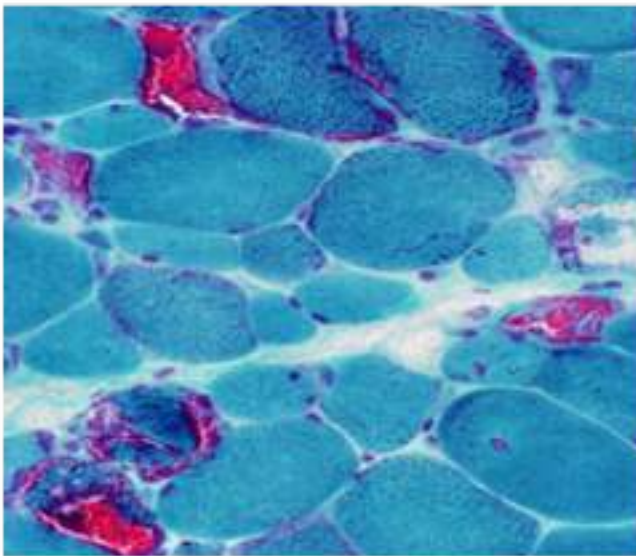
Ques No: 128

Subject: Pediatrics

Topic: Inborn Errors of Metabolism

Sub-Topic:

An 8-year old child has difficulty walking and getting up from a squatting position. A muscle biopsy was done and is as shown in the image. Which of the following is true about this condition?



O1:

Death occurs in 3rd decade

O2:

Previous history of viral prodrome

O3:

It is a mitochondrial storage disorder

O4:

d. Early treatment has excellent prognosis

Ans: 1

Ques No: 129

Subject: Physiology

Topic: Nerve Muscle Physiology

Sub-Topic:

A person after sleeping overnight with the arm under his head now experiences paresis but no numbness in the morning. Which of the following is the best explanation for it?

O1:
C fibers are more sensitive to pressure than A fibers

O2:
A fibers are more sensitive to hypoxia than B fibers

O3:
A fibers are more susceptible to pressure changes than C fibers

O4:
A fibers are more susceptible to hypoxia than C fibers

Ans: 3

Ques No: 130

Subject: Physiology

Topic: Cardiovascular System

Sub-Topic:

Which of the following mechanisms is seen in the baroreceptor reflex?

O1:
Feedforward

O2:
Positive feedback

O3:
Negative feedback

O4:
Adaptive control regulation

Ans: 3

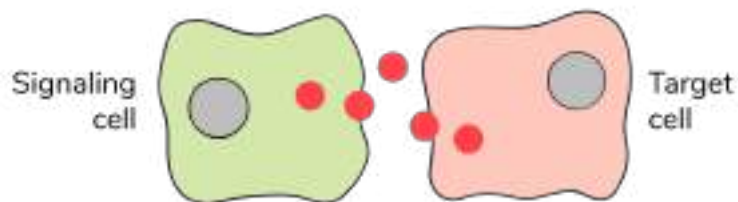
Ques No: 131

Subject: Physiology

Topic: General Physiology

Sub-Topic:

The image below depicts which of the following types of cell-to-cell signaling?



O1:
Paracrine

O2:
Autocrine

O3:
Endocrine

O4:
Merocrine

Ans: 1

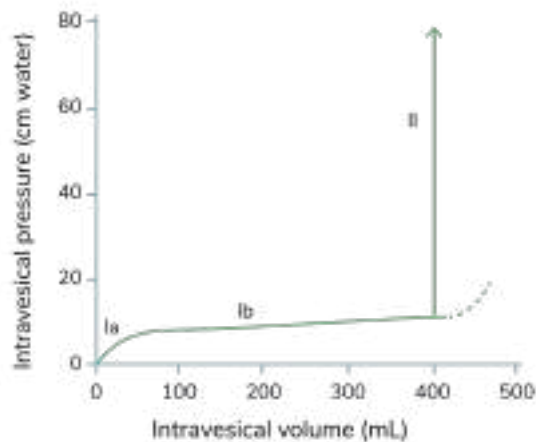
Ques No: 132

Subject: Physiology

Topic: Excretory System

Sub-Topic:

Which of the following statements is true regarding the given cystometrogram?



O1:
Segment Ia is due to residual urine

O2:
Segment Ib is due to Laplace law

O3:
Micturition fails to happen in segment II

O4:
The dotted line represents that micturition has occurred

Ans: 2

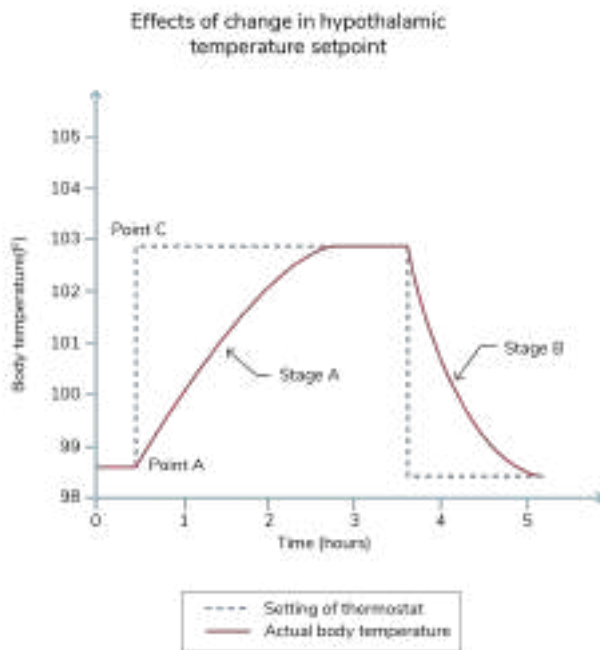
Ques No: 133

Subject: Physiology

Topic: The Nervous System

Sub-Topic:

In a patient, the hypothalamic thermostat was reset from point A to point C as shown below. Which of the following happens in stage A compared to stage B?



O1:
Shivering

O2:
Sweating

O3:
Increased blood flow to skin

O4:
Inhibition of chemical thermogenesis

Ans: 3

Ques No: 134

Subject: Physiology

Topic: The Nervous System

Sub-Topic:

A 65-year-old suffered from a stroke 2 days ago. He now presents with involuntary, violent, and flinging movements of the limbs on one side. What is the likely site of lesion in this patient?

O1:
Subthalamic nuclei

O2:
Globus pallidus

O3:
Putamen

O4:

Caudate nucleus

Ans: 1

Ques No: 135

Subject: Psychiatry

Topic: Eating Disorders

Sub-Topic:

A 16-year-old girl has intense cravings for food. She eats large amounts of food, which is followed by self-induced vomiting. What is the probable diagnosis?

O1:

Anorexia nervosa

O2:

Bulimia nervosa

O3:

Atypical depression

O4:

Binge eating disorder

Ans: 2

Ques No: 136

Subject: Psychiatry

Topic: Mood Disorders

Sub-Topic:

A woman, who is 4 days postpartum, presented with tearfulness, mood swings, and occasional insomnia. What is the likely diagnosis?

O1:

Postpartum depression

O2:

Postpartum blues

O3:

Postpartum psychosis

O4:

Postpartum anxiety

Ans: 2

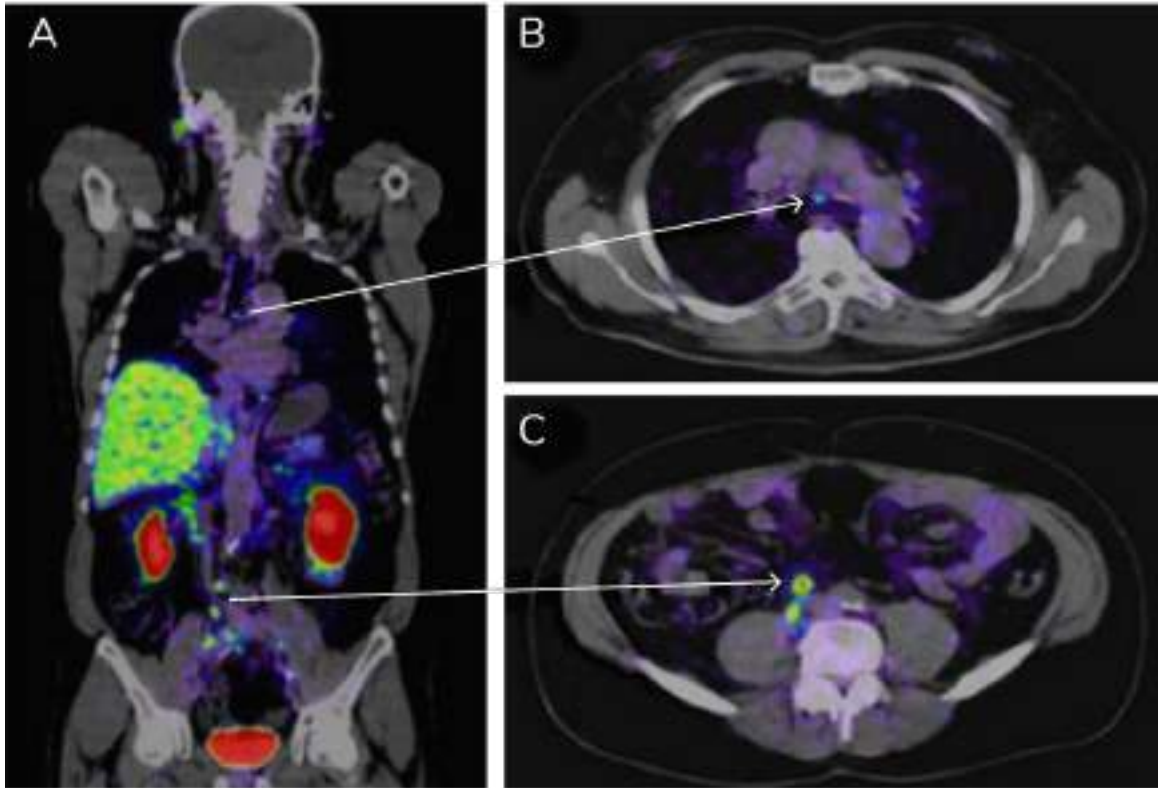
Ques No: 137

Subject: Radiology

Topic: Basics of Radiology

Sub-Topic:

Identify the image modality given below.



O1:
Cerebral blood flow scan

O2:
PET CT

O3:
Sestamibi scan

O4:
Full body MDCT

Ans: 2

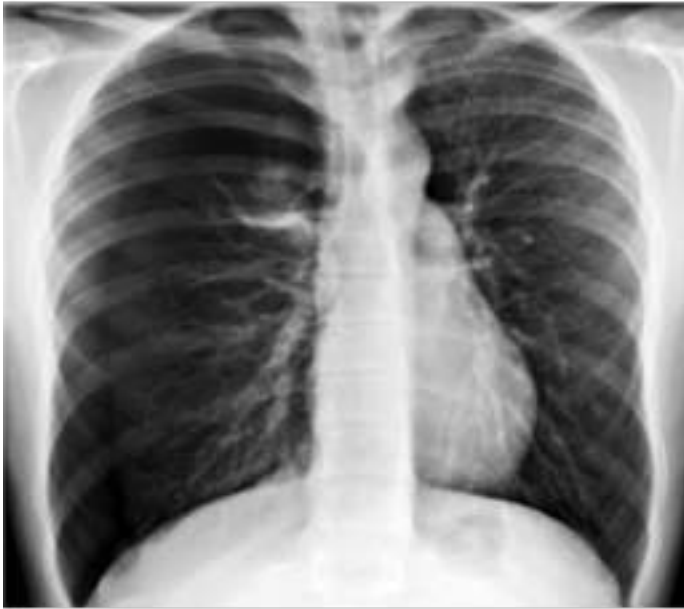Ques No: 138

Subject: Radiology

Topic: Thoracic Radiology

Sub-Topic:

A patient is brought to the casualty following a road traffic accident. On examination, the patient is conscious, BP is 90/60 mm Hg, respiratory rate is 40 breaths per minute, and pulse rate is 120 bpm. The X ray is shown below. What is the next step in management?



O1:
Chest tube insertion

O2:
Pericardiocentesis

O3:
Thoracotomy

O4:
Pleurodesis

Ans: 1

Ques No: 139

Subject: Pediatrics

Topic: Fluid and Electrolyte Disturbances

Sub-Topic:

A child presented with a history of loose stools with an increase in frequency of 4 days. On examination, he is drowsy, unable to feed, and skin on pinching goes back very slowly. According to the integrated management of neonatal and childhood illness (IMNCI), this child will be classified as having

O1:
Mild dehydration

O2:
Some dehydration

O3:
Severe dehydration

O4:

Moderate dehydration

Ans: 3

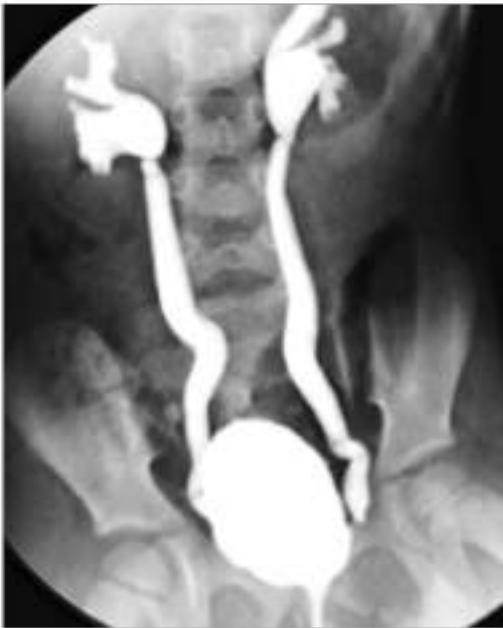Ques No: 140

Subject: Surgery

Topic: Urology

Sub-Topic:

A 6- year old boy came with a history of recurrent urinary tract infections. Imaging was done and is shown below. What is the diagnosis?



O1:

Vesicoureteric reflux

O2:

Urinary bladder diverticulum

O3:

Urinary bladder hernia

O4:

Vesicocolic fistula

Ans: 1

Ques No: 141

Subject: Surgery

Topic: Endocrine Surgery

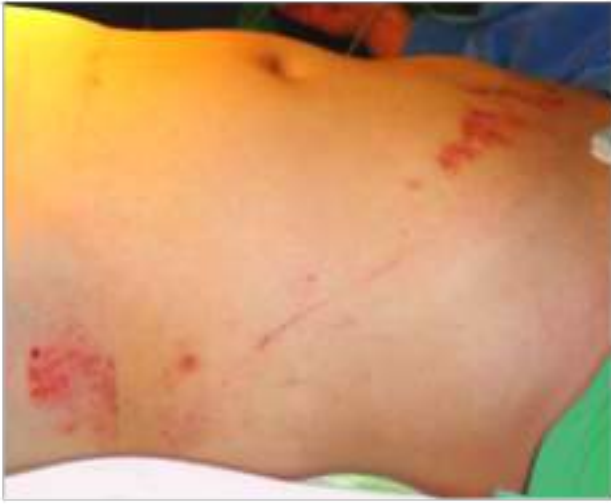Sub-Topic:

A 45-year-old female patient underwent a thyroidectomy. Three days after the surgery, she developed perioral numbness. Which of the following investigations need to be done for her?

O1: Free T3, T4
O2: T3, T4, thyroid–stimulating hormone
O3: Radioiodine scan
O4: Calcium, phosphate, and parathormone levels
Ans: 4

<p>Ques No: 142 Subject: Pediatrics Topic: Growth Sub-Topic:</p> <p>Which of the following children are considered at risk babies ?</p> <ol style="list-style-type: none"> 1. Baby with a birth weight of 2.5 kg 2. Baby on artificial feeds 3. Baby of working mother / single parent 4. Baby with weight <85% of expected weight 5. Birth order of 3 or more
O1: 2,3
O2: 1,2,3,4
O3: 4,5
O4: 1,4
Ans: 1

<p>Ques No: 143 Subject: Surgery Topic: Others Sub-Topic:</p> <p>A patient presented with blunt trauma to the abdomen. On evaluation, liver injury was noted, for which primary repair was done. Coagulation function was monitored intraoperatively, using the method shown below. What is the method used?</p>
--



O1:
Thromboelastography

O2:
Plethysmography

O3:
Sonography

O4:
Elastography

Ans: 1

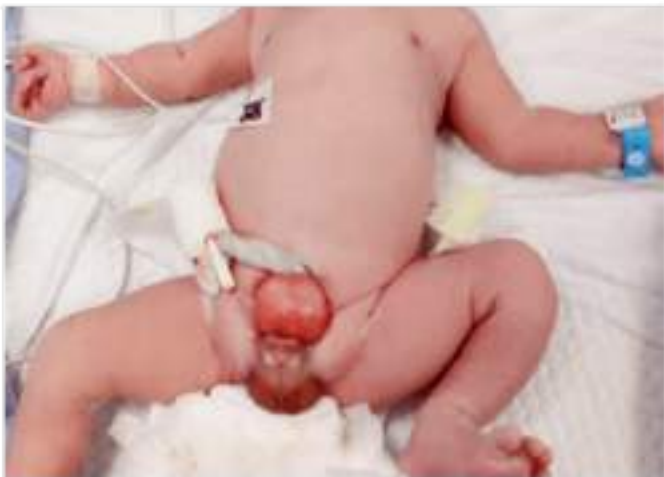Ques No: 144

Subject: Pediatrics

Topic: Pediatric Nephrology

Sub-Topic:

Identify the condition:



O1:
Bladder exstrophy

O2:
b.Omphalocele

O3:
c.Persistent vitellointestinal duct

O4:
Gastroschisis

Ans: 1

Ques No: 145

Subject: Surgery

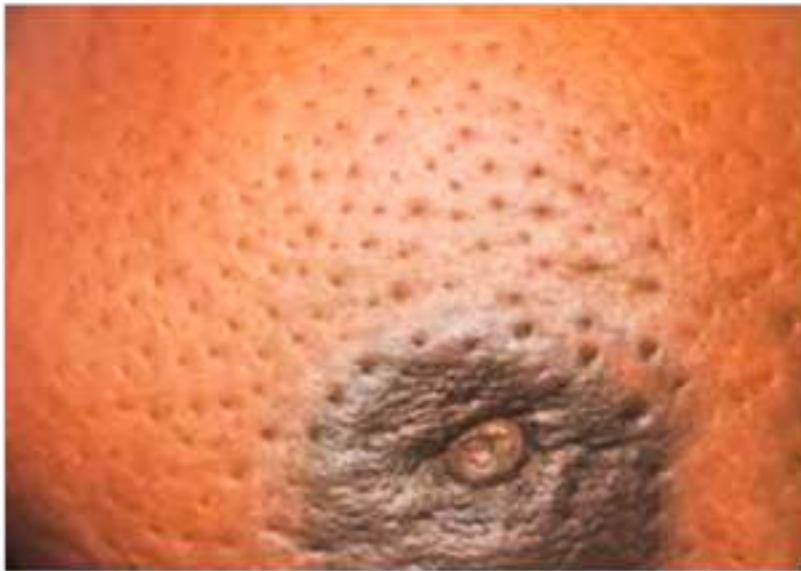Topic: Endocrine Surgery

Sub-Topic:

A 59-year-old lady presents with a progressive, painless lump in the breast. What is the cause for the following skin change?

O1:
Infiltration of subdermal lymphatics

O2:
Infiltration of the lactiferous duct



O3:

Involvement of Cooper's ligament

O4:
Spread of the tumor to the anterior chest wall

Ans: 1

Ques No: 146

Subject: Pediatrics

Topic: Pediatric Respiratory Disorders

Sub-Topic:

A previously healthy child presented with acute – onset dyspnea. A chest X – ray shows unilateral hyperinflation of the lungs. What is true for this patient ?

O1:

Focal area of decreased air entry will be suggestive of foreign body

O2:

Flexible bronchoscopy used for removal

O3:

In complete obstruction ball and valve mechanism causes hyperinflation

O4:

The child has developed acute laryngotracheobronchitis

Ans: 3

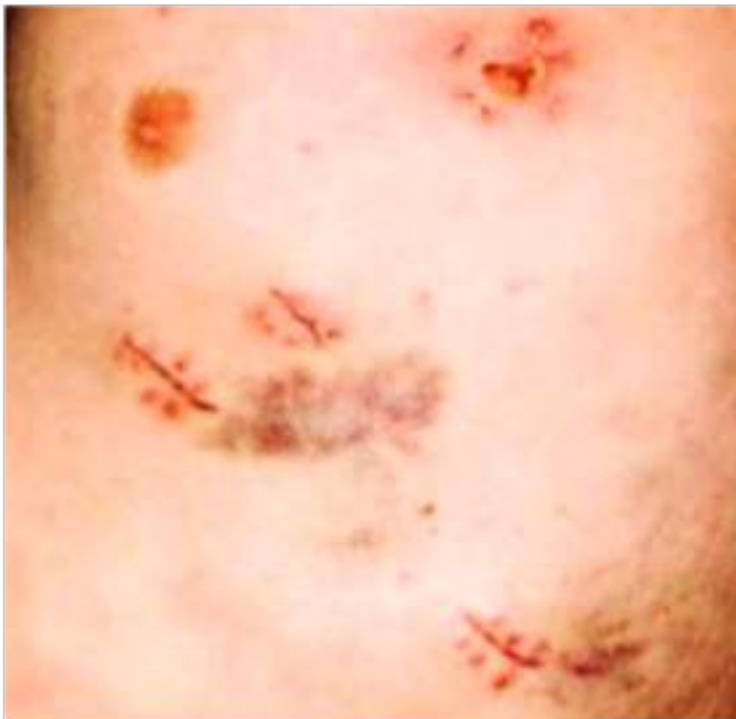Ques No: 147

Subject: Surgery

Topic: Others

Sub-Topic:

A child had a history of stab injury on the anterior abdominal wall, and the image is shown below. The child is hemodynamically stable. Which will be the next course of treatment?



O1: Emergency laparotomy
O2: Observation
O3: Intravenous hydration
O4: Wait and watch
Ans: 1

Ques No: 148 Subject: Pediatrics Topic: Musculoskeletal Disorders in Children Sub-Topic: A male child presented with arthralgia and abdominal pain. On examination, there was palpable purpura over the lower limbs. There is a past history of upper respiratory tract infection prior to the onset of presenting symptoms. Which of the following is the treatment for this condition?
O1: Azathioprine
O2: Methotrexate
O3: Cyclosporine
O4: Glucocorticoids
Ans: 4

Ques No: 149 Subject: Surgery Topic: Cardiothoracic Vascular Surgery Sub-Topic: Which of the following is most likely to be seen due to the rupture of a saccular aneurysm?
O1: Subdural hemorrhage
O2: Subarachnoid hemorrhage
O3: Intracerebral hemorrhage
O4: Hydrocephalus
Ans: 2

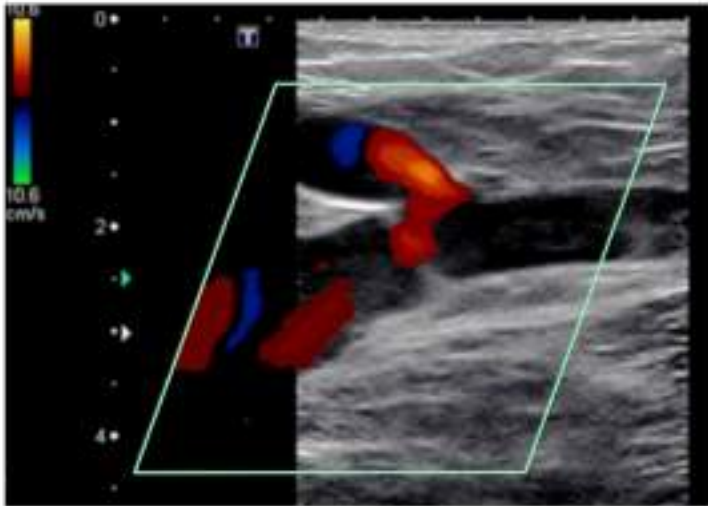
Ques No: 150

Subject: Surgery

Topic: Cardiothoracic Vascular Surgery

Sub-Topic:

A patient presents with sudden-onset right leg pain. An investigation was done, and the obtained image is shown below. What is the investigation?



O1:

A digital subtraction angiography

O2:

Ultrasound doppler

O3:

MR angiography

O4:

Plethysmography

Ans: 2

Ques No: 151

Subject: Pediatrics

Topic: Pediatric Nephrology

Sub-Topic:

A 10 year old presents with edema and anasarca. A diagnosis of minimal change disease is made. Which of the following is true about this condition?

O1:

Light microscopy shows effacement of podocytes

O2:

Good response to steroids

O3:

Most common in adults

O4:

Non selective proteinuria

Ans: 2

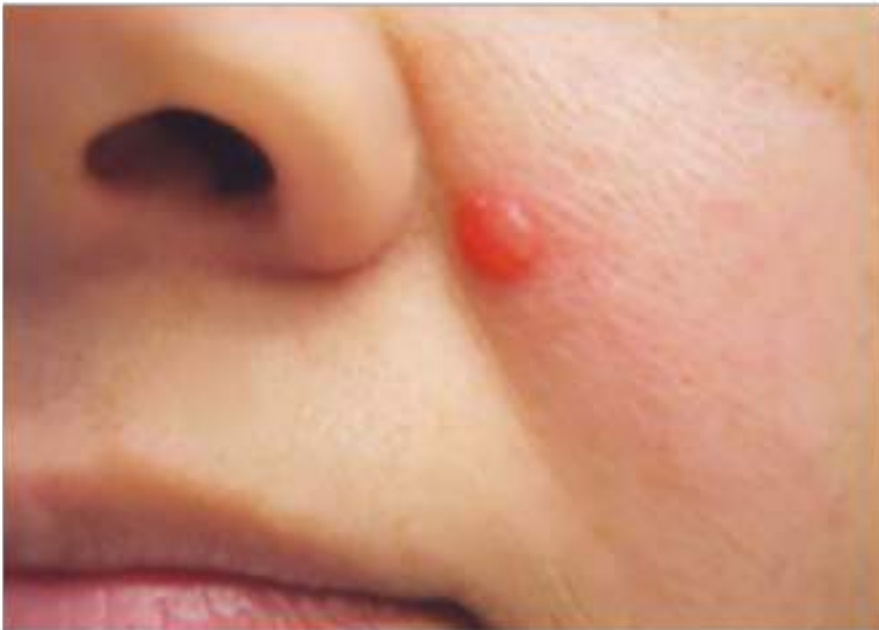Ques No: 152

Subject: Surgery

Topic: Plastic Surgery

Sub-Topic:

A male patient presented with a 0.3 cm nodule on the left nasolabial fold. It was excised, and a pathological examination was done. What is the diagnosis?



O1:

Basal cell carcinoma

O2:

Melanoma

O3:

Squamous cell carcinoma

O4:

Nevus

Ans: 1

Ques No: 153

Subject: Pediatrics

Topic: Pediatric Gastroenterology

Sub-Topic:

A 10-year old child presents with diarrhea and weight loss. On examination, the height and weight are lesser than expected. Laboratory investigations were positive for class II HLA-DQ2. Which of the following will you advise the child ?

O1:

Fat free diet

O2:

Lactose free diet

O3:

Low carbohydrate diet

O4:

Gluten free diet

Ans: 4

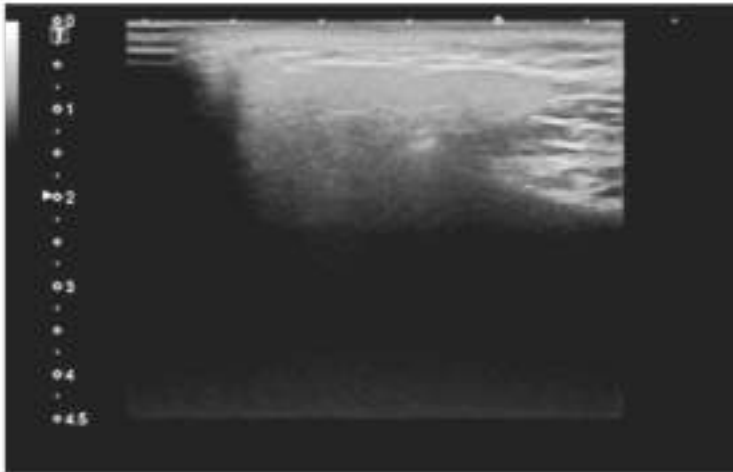
Ques No: 154

Subject: Surgery

Topic: Head And Neck

Sub-Topic:

A 45- year old patient complained of pain in one side of the neck. She is afraid of eating food as it worsens the pain. Ultrasound imaging of the salivary glands is done and shown below. What is the most likely diagnosis?



O1:

Sialolithiasis

O2:

Foreign body

O3:

Osteoma of the floor of the mouth

O4:

Cervical lymphadenopathy

Ans: 1

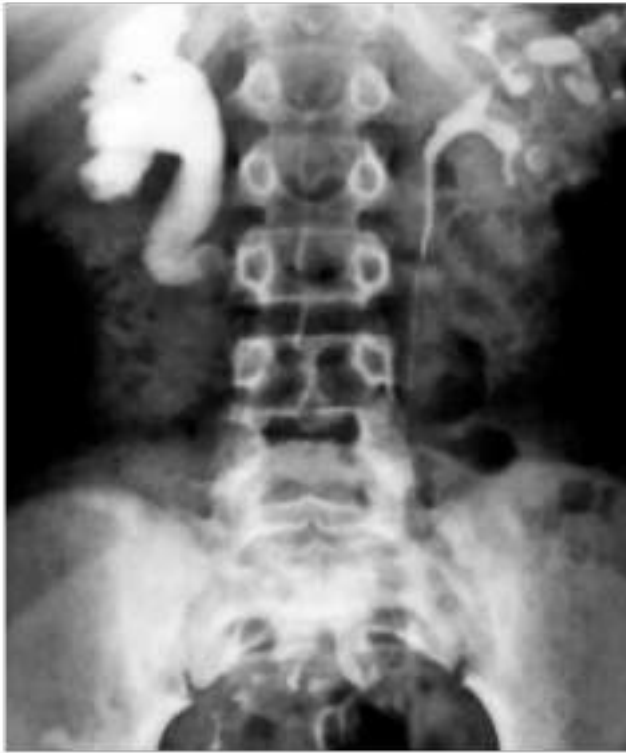Ques No: 155

Subject: Surgery

Topic: Urology

Sub-Topic:

A delayed intravenous urogram of a patient is given below. What is the likely diagnosis?



O1:

Pelviureteric junction obstruction

O2:

Putty kidney

O3:

Staghorn calculus

O4:

Cystic kidney

Ans: 1

Ques No: 156

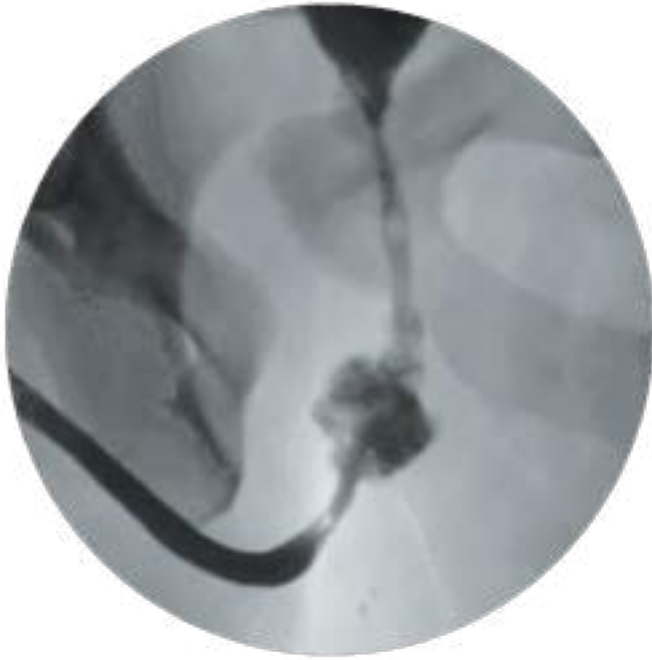Subject: Surgery

Topic: Others

Sub-Topic:

A young male patient with a history of a motor vehicle accident cannot pass urine. Blood is

seen at the meatus. What is the most likely site of urethral injury?



O1:
Bulbar urethra

O2:
Spongy urethra

O3:
Membranous urethra

O4:
Penile urethra

Ans: 3

Ques No: 157

Subject: Pharmacology

Topic: Respiratory Pharmacology

Sub-Topic:

A male patient with chronic obstructive pulmonary disease (COPD) was prescribed theophylline. He noticed that his urine output had increased the following day. This action of the drug is mediated through which of the following receptors?

O1:
. Interleukin – 10

O2:
Histone deacetylase

O3:
Adenosine A1

O4:

Beta 2 adrenergic receptors

Ans: 3

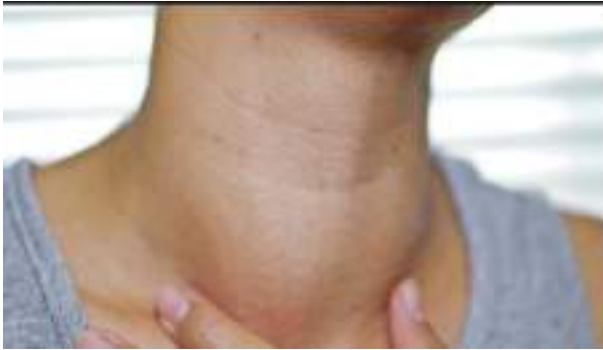Ques No: 158

Subject: Surgery

Topic: Endocrine Surgery

Sub-Topic:

A male patient presented with midline neck swelling. He later developed cervical node enlargement. The histopathology of the lesion is shown below. Which of the following statements is false about this condition?



O1:

Excellent prognosis is associated with this condition

O2:

It spreads quickly via lymphatics

O3:

Nuclear characteristics are used for the identification

O4:

Fine needle aspiration cytology (FNAC) is not diagnostic

Ans: 4

Ques No: 159

Subject: Pharmacology

Topic: Endocrine Pharmacology

Sub-Topic:

Which of the following drugs is not likely to cause Pulmonary fibrosis?

O1:

Metformin

O2:

Methotrexate

O3:

Bleomycin

O4:

Nitrofurantoin

Ans: 1

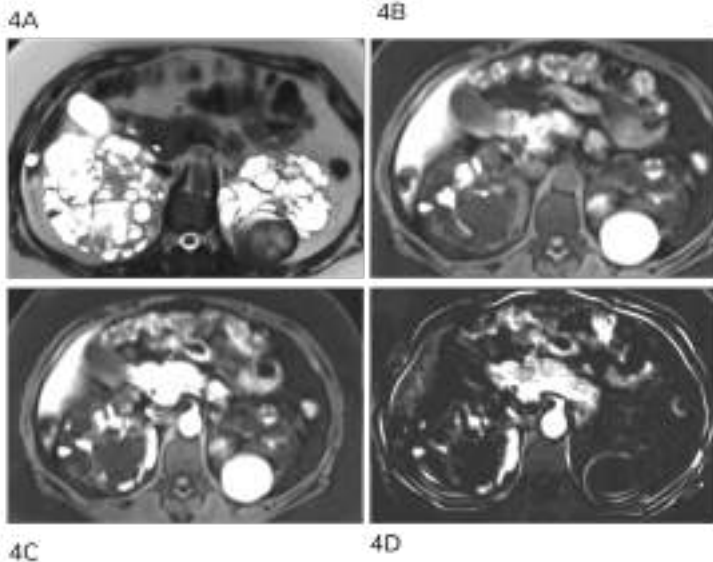
Ques No: 160

Subject: Surgery

Topic: Urology

Sub-Topic:

A 40-year-old man with a known case of hypertension presented with multiple episodes of hematuria and loin pain. His elder brother passed away due to a stroke at the age of 40. The ultrasound abdomen is shown below. What is the probable diagnosis?



O1:

Renal cell carcinoma

O2:

Autosomal dominant polycystic kidney disease

O3:

Tuberculosis of the kidney

O4:

Autosomal recessive polycystic kidney disease

Ans: 2

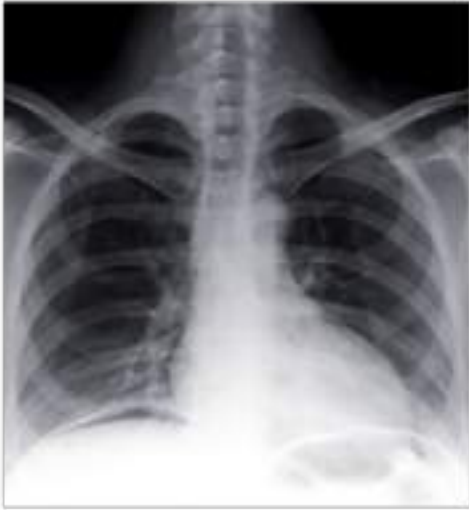Ques No: 161

Subject: Surgery

Topic: Gastrointestinal Surgery

Sub-Topic:

A patient presents with acute-onset, severe abdominal pain. He is hemodynamically stable. A chest X-ray is shown below. What is the next step in management?



O1:
Gastric lavage

O2:
Chest tube insertion

O3:
Tracheostomy

O4:
Resuscitation and laparotomy

Ans: 4

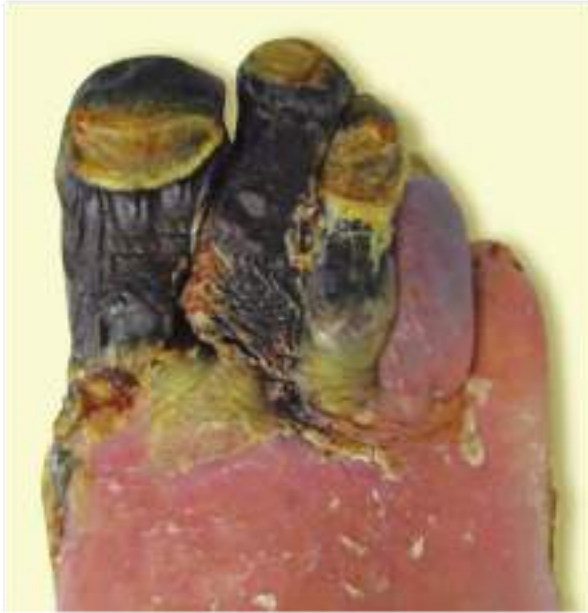Ques No: 162

Subject: Pharmacology

Topic: Drugs Affecting Blood and Blood formation

Sub-Topic:

A patient with deep vein thrombosis was started on a new drug. After 2 days, he presented with the given finding. Which of the following drugs is implicated in causing the above condition?



O1:
Warfarin

O2:
Heparin

O3:
Dabigatran

O4:
Rivarox

Ans: 1

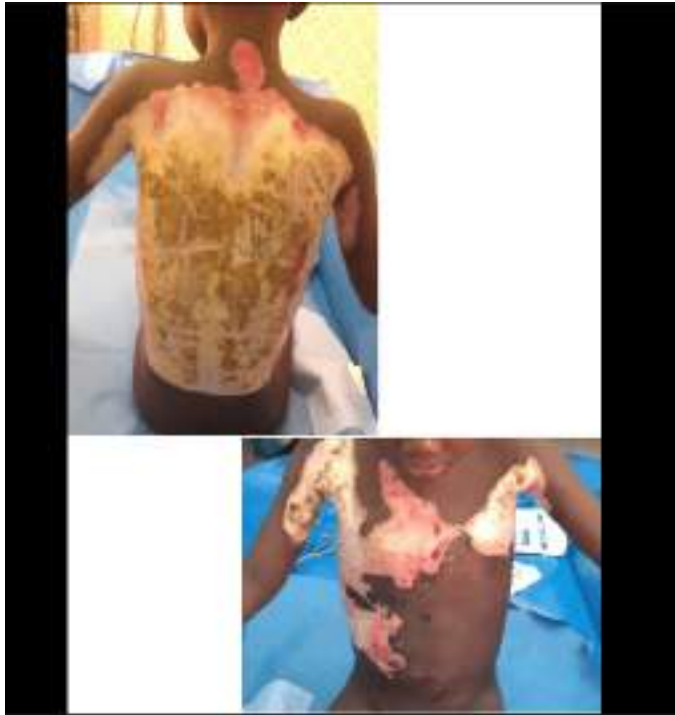
Ques No: 163

Subject: Surgery

Topic: Plastic Surgery

Sub-Topic:

Calculate the percentage of burns in a preschool child shown in the image below



O1:
15-20%

O2:
25-30%

O3:
35-40%

O4:
10-15%

Ans: 2

Ques No: 164

Subject: Pharmacology

Topic: Anticancer Drugs

Sub-Topic:

A patient undergoing chemotherapy was given an antiemetic, after which he developed symptoms like acute dystonia, bradykinesia, and tremors. Which of the following drugs would have caused these symptoms?

O1:
Ondansetron

O2:
Metoclopramide

O3:
Meclizine

O4:

Scopolamine

Ans: 2

Ques No: 165

Subject: Pharmacology

Topic: CVS Pharmacology

Sub-Topic:

A young patient started to take a weight loss medication that acts by inhibiting fat absorption from food. After a few weeks, she developed easy bruising and increased menstrual bleeding. Deficiency of which of the following vitamins is responsible for her condition?

O1:

Vitamin E

O2:

Vitamin K

O3:

Vitamin B6

O4:

Vitamin D

Ans: 2

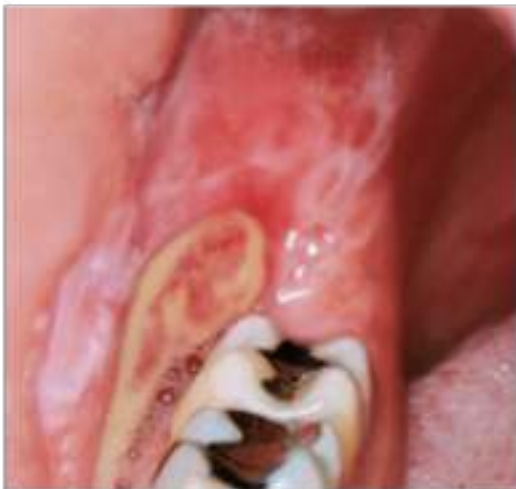Ques No: 166

Subject: Surgery

Topic: Head And Neck

Sub-Topic:

A 32-year-old patient who is a chronic alcoholic presents with oral ulcers and a burning sensation. A picture of the oral cavity is given below. What is the most likely diagnosis?



O1:

Leukoplakia

O2:
Erythroplakia

O3:
Submucosal fibrosis

O4:
Malakoplakia

Ans: 1

Ques No: 167

Subject: Pharmacology

Topic: Antimicrobials : Anti Bacterial Drugs

Sub-Topic:

A woman presenting with symptoms of urinary tract infection was prescribed a drug that causes tendon rupture and arthropathy. What is the mechanism of action of the drug?

O1:
DNA gyrase inhibition

O2:
Ribosomal inhibition

O3:
Cell wall synthesis

O4:
Inhibition of folic acid synthesis

Ans: 1

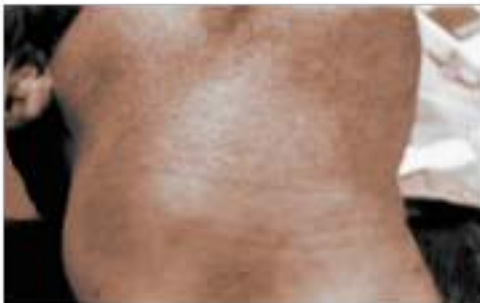Ques No: 168

Subject: Surgery

Topic: Cardiothoracic Vascular Surgery

Sub-Topic:

A patient presents with a tender pulsatile mass, as shown in the image below. What will be done next for this patient?



O1:
Ultrasound doppler

O2:
Needle aspiration

O3:

CT angiogram with percutaneous management

O4:

Intravenous antibiotics for 7 days

Ans: 1

Ques No: 169

Subject: Pharmacology

Topic: CVS Pharmacology

Sub-Topic:

A patient was brought to the emergency with a history of consumption of 8 tablets of digoxin. On examination he was unstable and his heart rate was 56 bpm. ECG showed a 3rd-degree heart block. What is the next step in the management of this patient?

O1:

a. Antibody against digoxin

O2:

Lidocaine

O3:

c. DC cardioversion

O4:

d. Phenytoin

Ans: 1

Ques No: 170

Subject: Pharmacology

Topic: Renal Pharmacology

Sub-Topic:

An elderly man, who is a known case of diabetic nephropathy, presented to the emergency with palpitations and chest discomfort. ECG showed tall T-waves. Laboratory investigations showed elevated potassium levels. Which of the following drugs will cause the shift of potassium back into the cell?

O1:

Epinephrine

O2:

b. Glucagon

O3:

c. Atropine

O4:

d. Lactic acid

Ans: 1

Ques No: 171

Subject: Pharmacology

Topic: Endocrine Pharmacology

Sub-Topic:

A patient with a pituitary tumor that overproduced growth hormone underwent surgical removal of the tumor. The resection was found to be incomplete. What is the first-line treatment for this patient?

O1:

Leuprolide

O2:

Goserelin

O3:

Nafarelin

O4:

Octreotide

Ans: 4

Ques No: 172

Subject: Pharmacology

Topic: Endocrine Pharmacology

Sub-Topic:

A middle-aged male patient presents with protrusion of the chin, excessive sweating, impaired glucose tolerance, and enlargement of hands and feet. Which of the following is a growth hormone receptor antagonist used to treat this condition?

O1:

Octreotide

O2:

Pegvisomant

O3:

Cabergoline

O4:

Olcegepant

Ans: 2

Ques No: 173

Subject: Surgery

Topic: Urology

Sub-Topic:

A patient presents with prostate carcinoma, which has now spread to the vertebra. What is the route of spread to the lumbar vertebra?

O1:

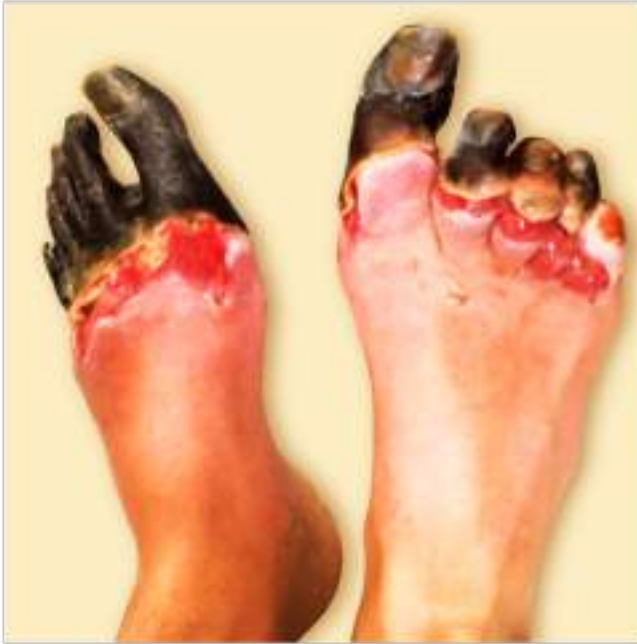Prostatic venous plexus

O2:

Transcoelomic spread
O3: Inferior vesical vein
O4: Internal iliac vein
Ans: 1

Ques No: 174 Subject: Pharmacology Topic: Chemotherapy of Specific Microbial Diseases Sub-Topic: A diabetic patient presented with rhinitis and facial swelling. An intranasal biopsy revealed the presence of broad-based aseptate hyphae with branching at right angle. Evidence of vascular invasion was present. What will be the drug of choice for this condition?
O1: Fluconazole
O2: Amphotericin B
O3: Ketoconazole
O4: Griseofulvin
Ans: 2

Ques No: 175 Subject: Surgery Topic: Cardiothoracic Vascular Surgery Sub-Topic: A male patient presents with impotence and bilateral resting pain. The following finding is seen in the legs. At which level has the pathology occurred?



O1:
Bilateral popliteal arteries

O2:
Bilateral internal iliac arteries

O3:
Aortoiliac bifurcation

O4:
Bilateral femoral arteries

Ans: 3

Ques No: 176

Subject: Pharmacology

Topic: Antimicrobials : Anti Bacterial Drugs

Sub-Topic:

A tuberculosis patient on anti-tubercular treatment presents with a tingling sensation and paresthesia in the lower limbs. He is not a diabetic and occasionally consumes alcohol. Which of the following vitamins must be supplemented to this patient?

O1:
Vitamin B6

O2:
Vitamin B12

O3:
Vitamin B2

O4:
Vitamin B3

Ans: 1

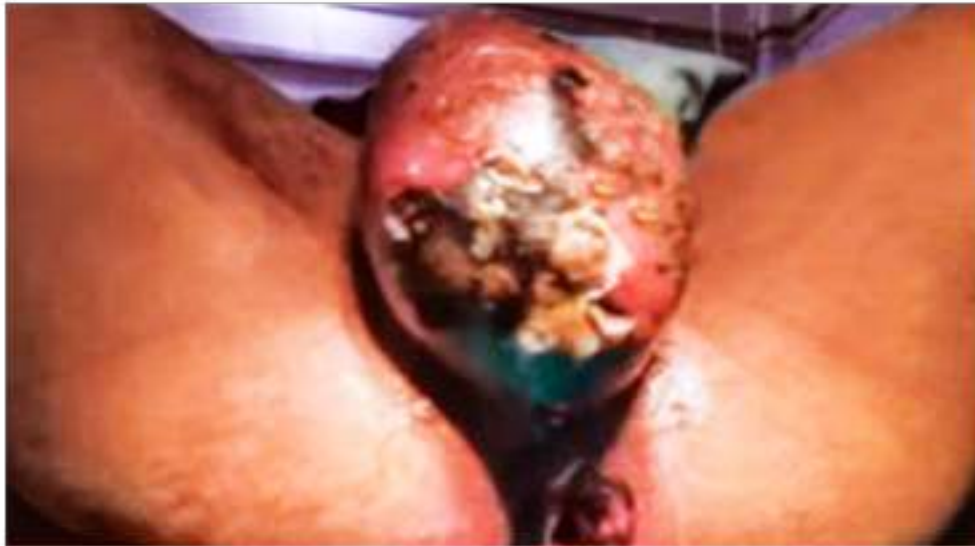Ques No: 177

Subject: Surgery

Topic: Urology

Sub-Topic:

An elderly male patient presented with a sudden onset of scrotal pain and discharge. Based on the image below, what is the likely diagnosis?



O1:

Torsion of testis

O2:

Acute epididymo-orchitis

O3:

Scrotal carcinoma

O4:

Fournier's gangrene

Ans: 4

Ques No: 178

Subject: Pharmacology

Topic: ANS Pharmacology

Sub-Topic:

An elderly woman received a botox injection for the treatment of wrinkles. Which of the following is the mechanism of action of botulinum toxin?

O1:

Inhibits the release of acetylcholine

O2: Release of noradrenaline at synaptic cleft
O3: Selectively and irreversibly inhibits nicotinic receptors
O4: Stimulates muscarinic and nicotinic receptors
Ans: 1

<p>Ques No: 179 Subject: Surgery Topic: Others Sub-Topic:</p> <p>Identify the fluid shown below on the basis of composition: Na⁺ 131mmol/L Cl⁻ 111 mmol/L Lactate 29 mmol/L K⁺ 5 mmol/L Ca²⁺ 2 mmol/L Total 279mOsm/L</p>
O1: Haemaccel
O2: Ringer lactate
O3: Isolyte
O4: Isolyte M
Ans: 2

<p>Ques No: 180 Subject: Pharmacology Topic: CVS Pharmacology Sub-Topic:</p> <p>Which of the following is a PCSK9 inhibitor?</p>
O1: Evolocumab
O2: Ezetimibe
O3: Bempedoic acid
O4: Clofibrate

Ans: 1

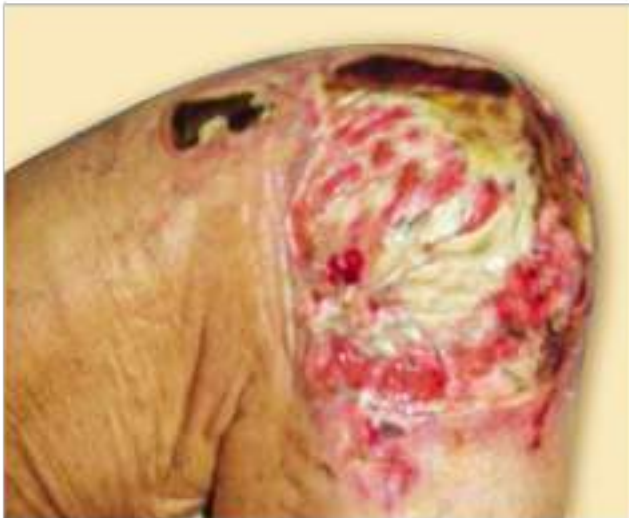Ques No: 181

Subject: Surgery

Topic: Others

Sub-Topic:

The image below shows a pressure sore. Which stage does this belong to?



O1:

Stage 1

O2:

Stage 2

O3:

Stage 3

O4:

Stage 4

Ans: 4

Ques No: 182

Subject: Pharmacology

Topic: CNS Pharmacology

Sub-Topic:

An elderly man presents with rigidity and tremors. On examination, he has blank facial expressions. Which of the following drugs can be used to manage this condition?

O1:

Clozapine

O2:

Donepezil

O3:

Selegiline

O4:

Haloperidol

Ans: 3

Ques No: 183

Subject: Surgery

Topic: Gastrointestinal Surgery

Sub-Topic:

Identify the most common site of an intraperitoneal abscess.

O1:

Suprahepatic

O2:

Subhepatic

O3:

Left lobe of liver

O4:

Left side below diaphragm

Ans: 2

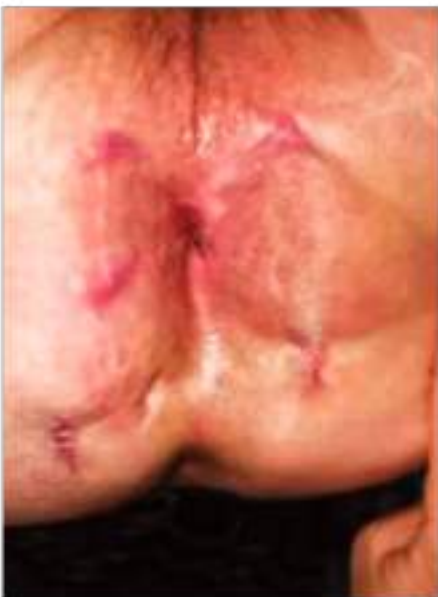Ques No: 184

Subject: Surgery

Topic: Gastrointestinal Surgery

Sub-Topic:

A man complained of recurrent discharge and pain due to lesions around the anus for 3 years. What is the diagnosis?



O1: Pilonidal sinus
O2: Carbuncle
O3: Boil
O4: Fistula in ano
Ans: 4

<p>Ques No: 185 Subject: Surgery Topic: Others Sub-Topic:</p> <p>According to triage, which of the following categories of patients comes under green?</p>
O1: Ambulatory patients
O2: Medium risk patients
O3: High-risk patients
O4: Dead patients
Ans: 1

<p>Ques No: 186 Subject: PSM Topic: Concept of Health and Disease Sub-Topic:</p> <p>The average life expectancy for a woman in Japan is 87 years. Due to recent advances in testing for cervical cancer, there is an increase in life expectancy by 15 years. The healthcare utility value is 0.8. Which of the following can be calculated from the parameters given?</p>
O1: HALE
O2: DALY
O3: DFLE
O4: QALY
Ans: 4

Ques No: 187

Subject: PSM

Topic: Allied Health Disciplines

Sub-Topic:

You are working in a primary health center (PHC) situated in a high seismic zone. Which of the following will you do as part of preparedness for an emergency?

1. Disaster preparedness by making sure all financial and other resources are available
2. Increase public awareness through campaigns and loudspeakers
3. Conduct a simulation for the disaster and assess the response
4. Follow instructions given over the phone or radio by higher officials

O1:

1,2,3,4

O2:

2,3,4

O3:

1,2,3

O4:

1,2,4

Ans: 3

Ques No: 188

Subject: PSM

Topic: Communicable and Non-communicable Diseases

Sub-Topic:

Although many animals are implicated in the spread of rabies, dogs are the most common ones. Also, it usually affects children in developing countries. Knowing this, what is the most cost-effective and logical way to reduce the incidence of rabies?

O1:

Testing all the dogs for rabies

O2:

Reduce stray dog population and vaccinate all dogs

O3:

Increase the laboratory facilities

O4:

Increase capacity of healthcare workers for surveillance

Ans: 2

Ques No: 189

Subject: PSM

Topic: National Health Programs

Sub-Topic:

Which of the following steps is not included in the STEP approach of WHO?
O1: Therapeutic assessment
O2: Physical assessment
O3: Psychological assessment
O4: Behavioral assessment
Ans: 1

<p>Ques No: 190 Subject: PSM Topic: National Health Programs Sub-Topic:</p> <p>A male patient diagnosed with tuberculosis took complete treatment. Sputum examination was done after the completion of the intensive and the continuation phases. It was found to be negative. What is the status of the patient?</p>
O1: Cured
O2: Treatment completed
O3: Lost to follow up
O4: Treatment failed
Ans: 1

<p>Ques No: 191 Subject: PSM Topic: Epidemiology Sub-Topic:</p> <p>A cohort study was conducted with drinkers and non-drinkers of green tea to study its effect on diabetes mellitus. The risk ratio was found to be 0.84. Which of the following statements is correct?</p>
O1: Green tea reduces the risk of diabetes
O2: Green tea increases the risk of diabetes
O3: Data insufficient to establish causal association
O4:

The value (0.85) tends to be close to 41, hence there is no effect

Ans: 1

Ques No: 192

Subject: PSM

Topic: Health Care of The Community in India

Sub-Topic:

Which statement refers best to the criteria for starting an urban community health center?

O1:

Caters to a population of 1-1.5 lakh

O2:

Referral center for 2-3 primary health centers

O3:

No sub-district and district hospitals present in the area

O4:

Should have a 100-bed facility in metro cities

Ans: 4

Ques No: 193

Subject: PSM

Topic: Allied Health Disciplines

Sub-Topic:

How is a broken vaccine vial disposed of, according to biomedical waste management?

O1:

Puncture proof blue bin

O2:

White container

O3:

Yellow container

O4:

Red container

Ans: 1

Ques No: 194

Subject: PSM

Topic: National Health Programs

Sub-Topic:

In an urban area in the state of Madhya Pradesh, a primigravida goes for institutional delivery after being motivated by an ASHA worker. What are the benefits they will receive (in terms of money in rupees) under the Janani Suraksha Yojana?

ASHA-Accredited social health activist

O1: 1000 for mother and 400 for ASHA
O2: 1400 for mother and 600 for ASHA
O3: 600 for mother and 400 for ASHA
O4: 400 for mother and 600 for ASHA
Ans: 1

<p>Ques No: 195 Subject: PSM Topic: International Health Sub-Topic:</p> <p>Which of the following agencies provides seed and manure in applied nutrition programs in schools?</p>
O1: CARE
O2: UNDP
O3: UNICEF
O4: WHO
Ans: 3

<p>Ques No: 196 Subject: PSM Topic: Epidemiology Sub-Topic:</p> <p>Many children from a particular community coming to a hospital were detected to have acute lymphoblastic leukemia (ALL). It was assumed that it is due to the presence of cytotoxic waste in the water of that community. If a case-control study has to be done to find whether the chemical and ALL are associated, what will be taken as the control?</p>
O1: Children from the area exposed, but unaffected with the disease
O2: Children from the area not exposed and affected with the disease
O3: Children coming to your OPD, who do not have the disease
O4: All children with ALL irrespective of exposure status

Ans: 1

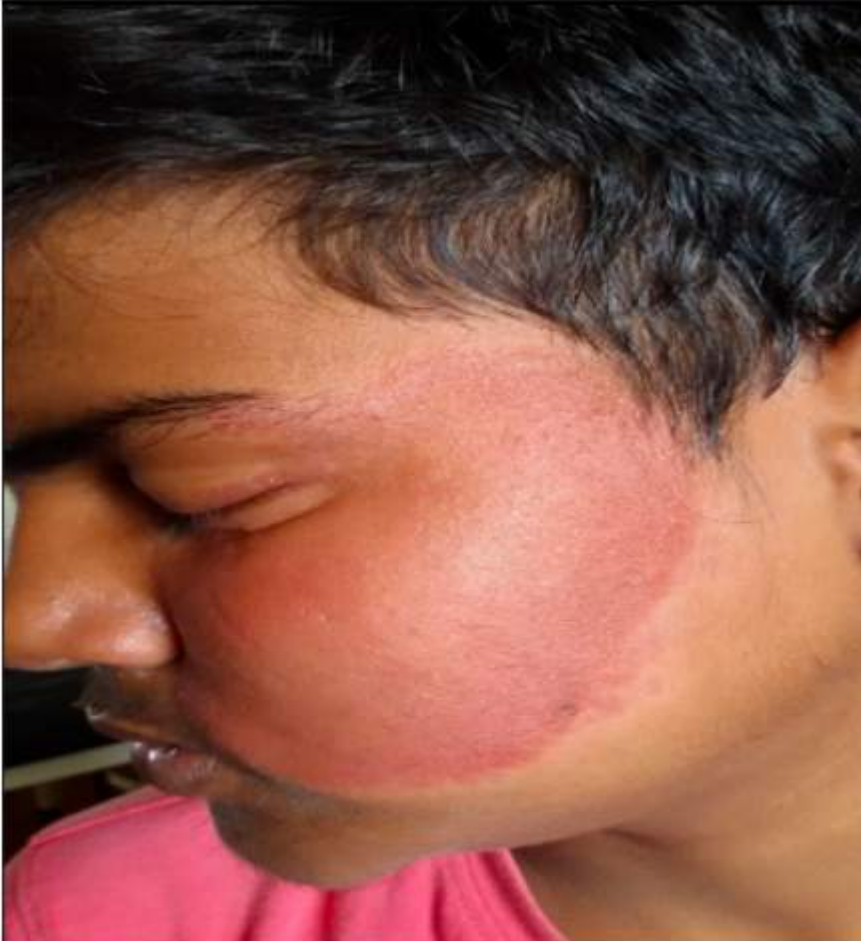Ques No: 197

Subject: Dermatology

Topic: Integrated Essentials

Sub-Topic:

A patient presents with an anesthetic patch in the areas on the face, as shown in the image below. Which of the following nerves is the most commonly involved in this condition?



O1:
Abducens nuclei

O2:
Facial nerve

O3:
Optic nerve

O4:
Trigeminal nerve

Ans: 2

Ques No: 198

Subject: PSM

Topic: Vaccines and Cold Chain

Sub-Topic:

An auxiliary nurse midwife has to conduct a vaccination camp in a village. She received 2 open vials, one of which is a pentavalent vaccine and the other is an MR vaccine. What can she do regarding the utilization of these vials?

O1:

Use MR vaccine and discard pentavalent vaccine

O2:

Use both

O3:

Use pentavalent vaccine and discard MR vaccine

O4:

Discard both

Ans: 3

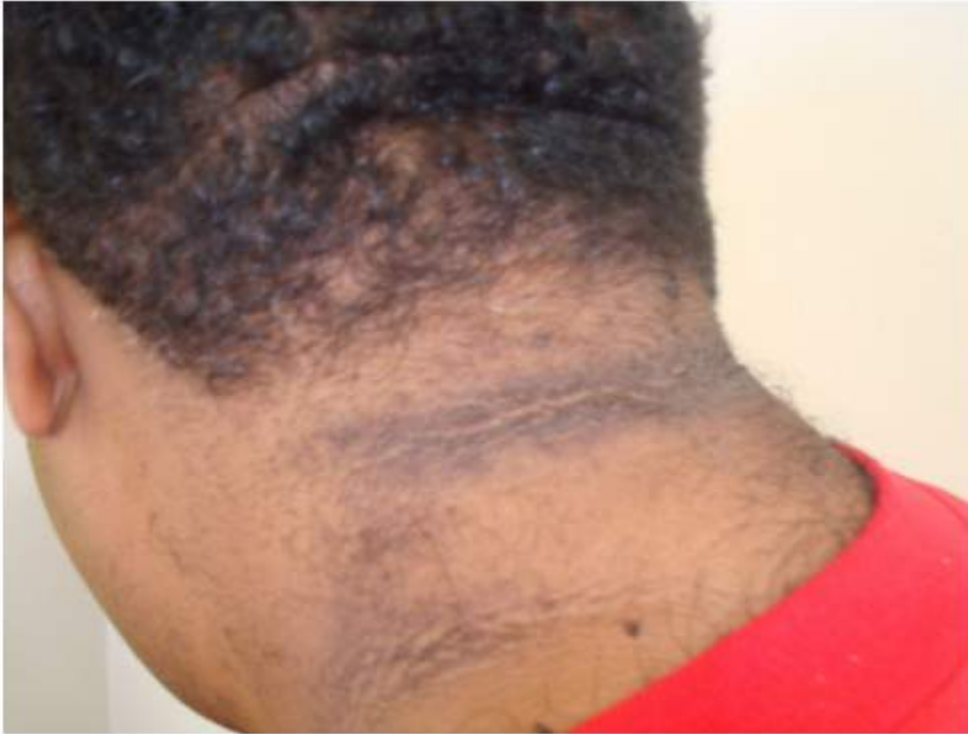Ques No: 199, QuesID : 793324

Subject: Dermatology

Topic: Pigmentary Disorders

Sub-Topic:

A female patient with a body mass index of 30 kg/m² presents to you with a lesion on the neck, as shown below. Which of the following conditions is the most likely to be suffering from?



O1:
Hypothyroidism

O2:
Metabolic syndrome

O3:
Addision's disease

O4:
Hyperparathyroidism

Ans: 2

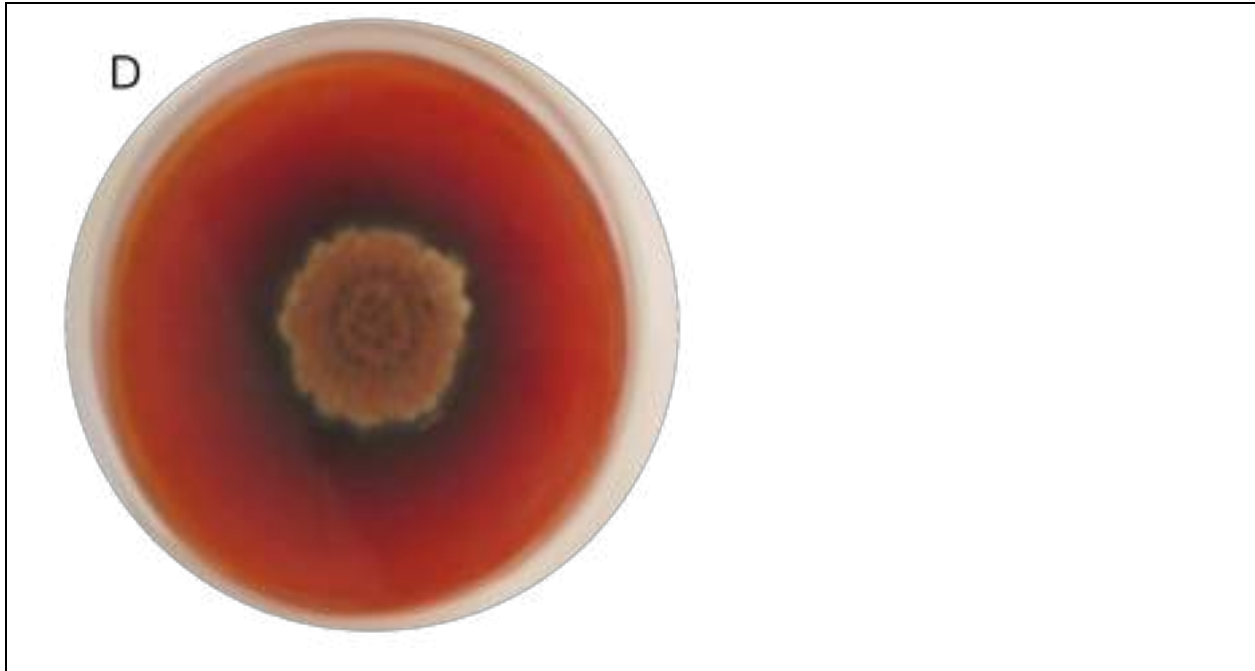
Ques No: 200, QuesID : 793342

Subject: Microbiology

Topic: Mycology

Sub-Topic:

A patient with cervical lymphadenopathy and is found to be retropositive. A fungal culture depicts a velvety growth with red diffusible pigment on the underside, as shown below. Which is the most likely causative organism?



O1:
Talaromyces marneffeii

O2:
Blastomyces

O3:
Aspergillus

O4:
Pneumocystis jirovecii

Ans: 1

If you wish to access the detailed explanations for the correct and incorrect options of these questions, download the PrepLadder app now.

Download PrepLadder's [NEET PG app for Android](#)

Download PrepLadder's [NEET PG app for iOS](#)

